

CASE REPORT

FIRST REPORTED CASE OF CEMENTO OSSIFYING FIBROMA OF PARANASAL SINUS TREATED WITH RADIATION IN HUMAN BEING

Kanhu Charan Patro¹, Siva G. Prasad², E. B. Rajmohan³, Arun C. Prabhu⁴, Subhra Das⁵, Muralikrishna Voonna⁶

HOW TO CITE THIS ARTICLE:

Kanhu Charan Patro, Siva G. Prasad, E. B. Rajmohan, Arun C. Prabhu, Subhra Das, Muralikrishna Voonna. "First Reported Case of Cemento Ossifying Fibroma of Paranasal Sinus Treated with Radiation in Human Being". Journal of Evolution of Medical and Dental Sciences 2015; Vol. 4, Issue 34, April 27; Page: 5956-5959, DOI: 10.14260/jemds/2015/872

ABSTRACT: Here we are reporting a case of cemento ossifying fibroma (COF) of paranasal sinus in a 45 year female presented with large mass in maxilla and extraosseous component, pain and disfigurement due to facial asymmetry and planned for surgery as the surgery is the main stay of treatment, reviewed with surgical oncologist and it was unresectable because of large extensive mass. Then we planned for radiation therapy as there was no other option available. We reviewed with literature there was not a single case treated with radiation in human being but reports are available treated with radiation therapy in horses and in other animals. On the basis of animal case reports we treated with radiation therapy. After treatment patient was improved symptomatically and living for 2 years till today. Here we are reporting this case and this may be the first reported case treated with radiation therapy in human being as per the literature available.

CASE DETAIL: 45 year old female presented with nasal obstruction, Facial swelling, Proptosis left eye [Fig. 1], Pain due to expansion of tumour, duration of more than one year. CT scan showed Mass involving bilateral maxillary sinus, eroding the pterygoid plates, destruction of sphenoid sinus, involving the orbital cavity and pushing of right eye outwards [Fig. 2]. Tumour volume on imaging was 250cc approx. biopsy of the tumour showed [Fig. 5] cement ossifying fibroma. Because of huge mass, bony involvement, surgery was not feasible sent for radiation oncologist for opinion. Radiation planning was done by intensity modulated radiotherapy technique [Fig. 3] with an aim of sparing the opposite optical apparatus. Plan evaluated with acceptable constraint specification planned for 50Gy in 25 fractions. Patient completed radiation therapy over 5 weeks and with dry desquamation of skin [RTOG grade II]. Patient planned for radiation and total dose delivered 50Gy @2Gy/# Over 5 weeks. Only primary treated and lymph node spared. Patient completed radiation with RTOG grade 2 skin reactions [dry desquamation]. There was no significant morphological change at the end of radiation. At 3 month follow-up Proptosis decreased, facial swelling came down [Fig. 4], Patient was symptom free, planned for imaging, CT scan showed decrease in tumour volume to 170cc and planned for next visit after 3 months. At the end of the treatment the response evaluated morphologically and which is an insignificant response, then patient was kept under follow up. After 3 months the Proptosis decreased, pain was minimal and patient was better than before. CT scan volume revealed around 170 cc comparing pre radiation volume of 250cc.

DISCUSSION: Cemento ossifying fibroma [COF] IS a bony origin of benign cause.^[1] WHO classifies COF as a fibro-osseous neoplasm, included among the non-odontogenic tumors, derived from the mesenchymal blast cells of the periodontal ligament, and with a potential to form fibrous tissue,

CASE REPORT

cement and bone, or a combination of such elements.^[2] It is mostly seen in maxilla, predominantly seen in females, mostly in 2nd to 3rd decade of life.^[3,4]

Clinically the patients present with slow growing asymptomatic mass in the paranasal site, when it breaks the periosteum, they presented with pain, facial asymmetry, sometimes it involves the orbital plates and patients presented with Proptosis which are seen in our case.

Pathologically it mostly comprises of fibrous, ossification with cement formation. Ossifying fibroma and cemento-ossifying fibroma represent two extremes of the same disease process since histologically both contain bone and cementum.^[5]

Radiologically, in most modern techniques on computed tomography, usually the mass in paranasal area with soft tissue mass of mixed density, well defined, sclerotic to lytic bony destruction, with calcification expansion of adjacent area are seen.^[6]

Surgery is the most desirable option; frequently from mandible and facial bones If not removed completely recurrence is common.^[7] Radiation therapy is reserved for recurrent and incomplete excision cases. Radiation therapy offered in most of the cases which are reported in literature was on animal (horses) studies and not a single case reported in human studies.^[8,9,10]

Radiation therapy used to treat malignant tumours. The main mechanism of radiation is to treat with ionizing radiation to stop growth by DNA damage. It is also indicated in various benign cases. Here we have treated on the basis of animal case reports and role of radiation on benign cases.^[11] We have treated with megavoltage linear accelerator to a total dose of 50 Gy by highly conformal radiotherapy called intensity modulated radiotherapy. After the treatment patient was symptomatically better and there is radiologically regression also. This is the first case in literature where we treated with radiation as extreme indication in a human being. Benign conditions can be taken care when there is no option. The response should not be expected as for malignant condition. Radiation usually takes care of rapidly proliferating tissue. As benign it is a slow growing tumour, response evaluation as not like others-it will take time to decrease the volume. Hypofractionation schedule may be tried. Needs more cases to reach the conclusion about dose fractionation schedule, response etc.

REFERENCES:

1. Galdeano-Arenas M, Crespo-Pinilla JI, Álvarez-Otero R, Espeso-Ferrero A, Verrier-Hernández A. Fibroma cemento-osificante gingival mandibular. presentación de un caso. *Med Oral*. 2004; 9: 176-9.
2. Ossifying fibromas of the jaw bone: 20 cases. Liu Y, Wang H, You M, Yang Z, Miao J, Shimizutani K, Koseki T *Dentomaxillofac Radiol*. 2010 Jan; 39 (1): 57-63.
3. Ossifying fibroma in the nasopharynx. A case report. Cakir B, Karadayi N *Clin Imaging*. 1991 Oct-Dec; 15 (4): 290-2.
4. Waldron CA. Fibro-osseous lesions of the jaws. *J Oral Maxillofac Surg*. 1993; 51: 828-35.
5. Slootweg PJ, Panders AK, Koopmans R, Nikkels PG. Juvenile ossifying fibroma. An analysis of 33 cases with emphasis on histopathological aspects. *J Oral Pathol Med* 1994; 23: 385-8.
6. Galdeano-Arenas M, Crespo-Pinilla JI, Alvarez-Otero R, Espeso-Ferrero A, Verrier-Hernandez A. Fibroma cement-osificante gingival mandibular. Presentacion de un caso. *Med Oral* 2004; 9: 176-9.

CASE REPORT

7. Rangil JS, Silvestre FJ, Bernal JR. Cemento-ossifying fibroma of the mandible: Presentation of a case and review of the literature. *J Clin Exp Dent*. 2011; 3: e66-9.
8. The use of megavoltage radiation to treat juvenile mandibular ossifying fibroma in a horse, Sarah C. Robbins, Mimi Arighi, Gerry Ottewell, *Can Vet J* 1996; 37: 683-684.
9. Radiotherapy of a recurrent ossifying fibroma in the paranasal sinuses of a horse. Orsini JA, Baird DK, Ruggles AJ. *J Am Vet Med Assoc*. 2004 May 1; 224 (9): 1483-6, 1454.
10. The use of megavoltage radiation to treat juvenile mandibular ossifying fibroma in a horse. Robbins SC, Arighi M, Ottewell G. *Can Vet J*. 1996 Nov; 37 (11): 683.
11. Radiation Therapy of Benign Diseases. A Clinical Guide, Authors: Stanley E. Order MD, ScD, FACR, Sarah S. Donaldson MD, FACR, ISBN: 978-3-642-97162-4.

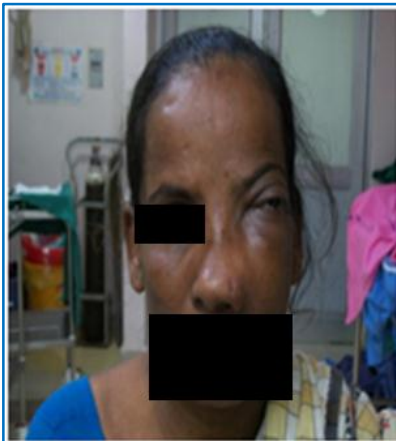

Fig. 1: Before treatment the facial asymmetry and proptosis

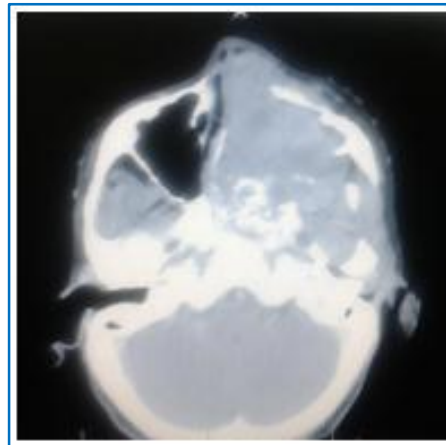


Fig. 2: Before treatment the computed tomography picture

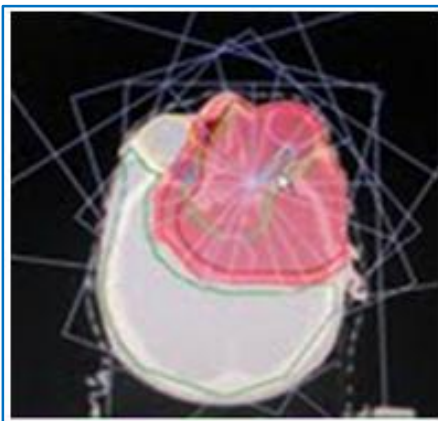


Fig. 3: Radiation treatment with IMRT. Sparing of opposite optic apparatus

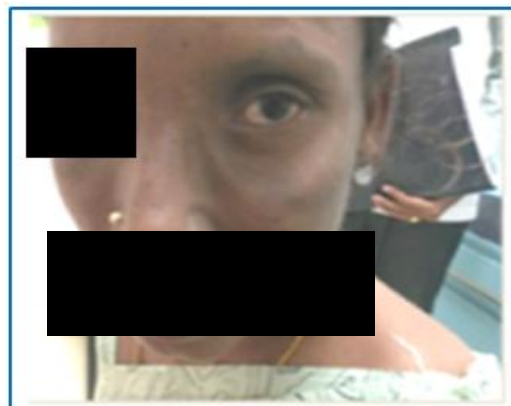

Fig. 4: After treatment the facial asymmetry and Proptosis decreased

CASE REPORT

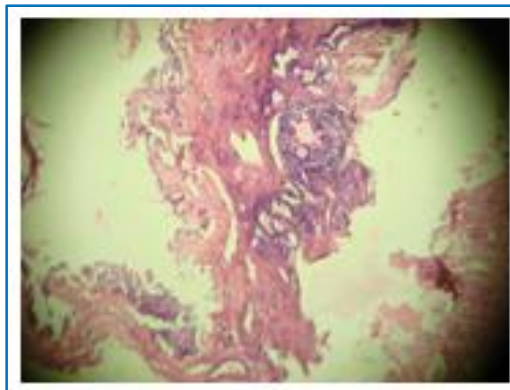


Fig. 5: Histopathology picture

AUTHORS:

1. Kanhu Charan Patro
2. Siva G. Prasad
3. E. B. Rajmohan
4. Arun C. Prabhu
5. Subhra Das
6. Muralikrishna Voonna

PARTICULARS OF CONTRIBUTORS:

1. HOD, Department of Radiotherapy, Mahatmagandhi Cancer Hospital & Research Institute, Visakhapatnam, Andhra Pradesh.
2. Assistant Professor, Department of Orthopaedics, KIMS, Ammalapuram, Andhra Pradesh.
3. Chief Medical Physicist, Department of Medical Physicist, Mahatmagandhi Cancer Hospital & Research Institute, Visakhapatnam, Andhra Pradesh.

FINANCIAL OR OTHER

COMPETING INTERESTS: None

4. Medical Physicist, Department of Medical Physicist, Mahatmagandhi Cancer Hospital & Research Institute, Visakhapatnam, Andhra Pradesh.
5. Medical Physicist, Department of Medical Physicist, Mahatmagandhi Cancer Hospital & Research Institute, Visakhapatnam, Andhra Pradesh.
6. HOD, Department of Surgical Oncology, Mahatmagandhi Cancer Hospital & Research Institute, Visakhapatnam, Andhra Pradesh.

NAME ADDRESS EMAIL ID OF THE CORRESPONDING AUTHOR:

Dr. Kanhu Charan Patro,
HOD, Department of Radiotherapy,
Mahatmagandhi Cancer Hospital & Research
Institute, MVP Colony,
Visakhapatnam, Andhra Pradesh.
E-mail: drkcpatro@gmail.com

Date of Submission: 02/04/2015.

Date of Peer Review: 03/04/2015.

Date of Acceptance: 17/04/2015.

Date of Publishing: 27/04/2015.