

## CASE REPORT

---

### UNUSUAL CASE OF ENDOMETRIOSIS CAUSING MENOPAUSE LIKE STATE IN A 17 YEAR OLD UNMARRIED GIRL

Swati Gawai<sup>1</sup>, Sumit Paranjpe<sup>2</sup>, Pradnya Changede<sup>3</sup>, Nirranjan Chavan<sup>4</sup>

#### HOW TO CITE THIS ARTICLE:

Swati Gawai, Sumit Paranjpe, Pradnya Changede, Nirranjan Chavan. "Unusual Case of Endometriosis Causing Menopause Like State in a 17 Year Old Unmarried Girl". Journal of Evolution of Medical and Dental Sciences 2015; Vol. 4, Issue 62, August 03; Page: 10872-10875, DOI: 10.14260/jemds/2015/1570

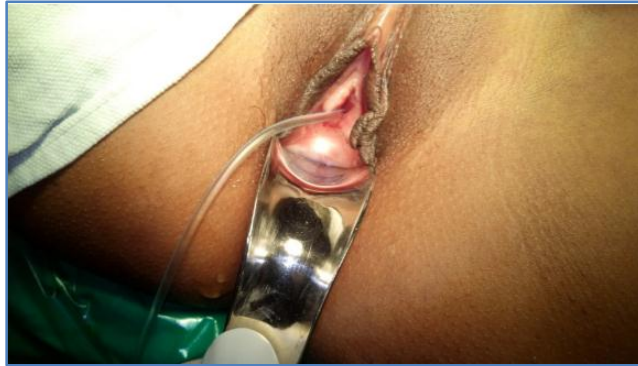**ABSTRACT:** An unusual case of a 17yr old unmarried girl presented with cyclical abdominal pain and blind vaginal pouch. Previously at the age of 14yrs during her menarche, she had a transverse vaginal septum due to which she had cryptomenorrhoea causing hematocolpus and hematometra. She was operated for the same during that time elsewhere (As the discharge notes suggests) excision of transverse vaginal septum and establishing a connection between the uterus and the vagina. After 3 months of that operation, she again had no menses for as long as 5yrs and after which she presently came to us with cyclical abdominal pain. During her laparotomy we found a right sided endometrioma and a lot of pelvic adhesion suggesting endometriosis. We tried to establish a connection between the uterus and the vagina by opening the uterus from above and to our surprise there was no hematometra or hematocolpus and only a thin endometrial lining.

**KEYWORDS:** Endometriosis, haematometra, hypoplastic uterus, vaginal septum.

**CASE REPORT:** Miss ABC, 17yr old unmarried female came to our opd with the chief complaints of amenorrhoea since 5years and a vague cyclical abdominal pain since past 5 yrs. No H/O associated fever, white discharge per vaginum & no other associated complaints. She presented with a history of pain in abdominal at the age of 14 during her menarche for which she was admitted to a local hospital and was found to have a transverse vaginal septum. Patient was operated for the same and as the previous discharge summary suggests, she was operated by resecting the transverse vaginal septum and achieving a connection between the uterus and the vagina. She was apparently kept with vaginal dilators post-surgery and was discharged within few days. Following her discharge from the hospital, she had regular menses every month for the next 3cycles after which she stopped having her menses. This was followed by a period of 5years amenorrhoea. She did not seek any medical help. She visited our hospital in the month of august and was admitted to gynaec ward.

**On Examination:** Patient was conscious co-operative,, Afebrile, Pulse – 86/min in left upper arm in supine position, Blood Pressure–120/80mm of hg, Respiratory System –bilateral air entry equal, Cardiovascular system –S1 S2 normal, Per abdominal examination -soft supple, no guarding, rigidity and tenderness. Per speculum examination showed a short vagina ending as a blind pouch. Per vaginal examination also confirmed the findings of a blind pouch.

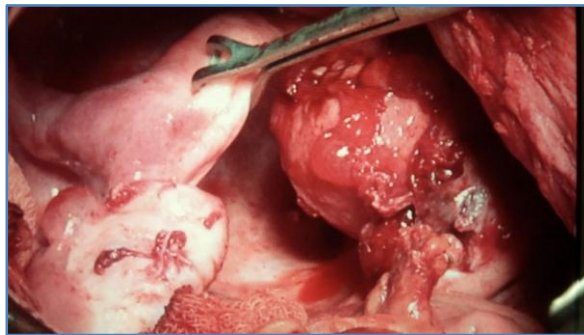
## CASE REPORT



**Fig. 1:Blind vaginal pouch**

Per rectal examination revealed an anteverted uterus with a boggy swelling in the right fornix. Pelvic MRI showed uterus measuring 5X3.4X3.4cms with an ET of 8mm, bilateral normal ovaries. A 5.3cmx1.8cm hyperintense lesion noted in the right iliac fossa s/o pelvic endometrioma. Small endometrioma was also noted over the urinary bladder. Her serum LH and FSH levels were very low. FSH-2.1mIU/ml (Normal range 14 to 40), LH – 0.6mIU/ml (Normal range 2 to 10), whereas her thyroid and prolactin levels were within normal limit. We performed examination under anaesthesia, with incision on the blind pouch under guidance and vision. After laparoscopy, insitu findings were: hypoplastic uterus with right sided 5X5cm endometrioma with pelvic adhesions. Patients consent taken for exploratory laparotomy after laparoscopy in a hope to reestablish a connection between the uterus and the vagina from above.

In situ findings of laparotomy: A lot of pelvic adhesion were seen in pouch of douglus which were separated and right sided 5cmX3cm endometrioma was excised during the procedure. A small atrophic hemi uterus was seen beside the right hemi uterus entirely separate from it.



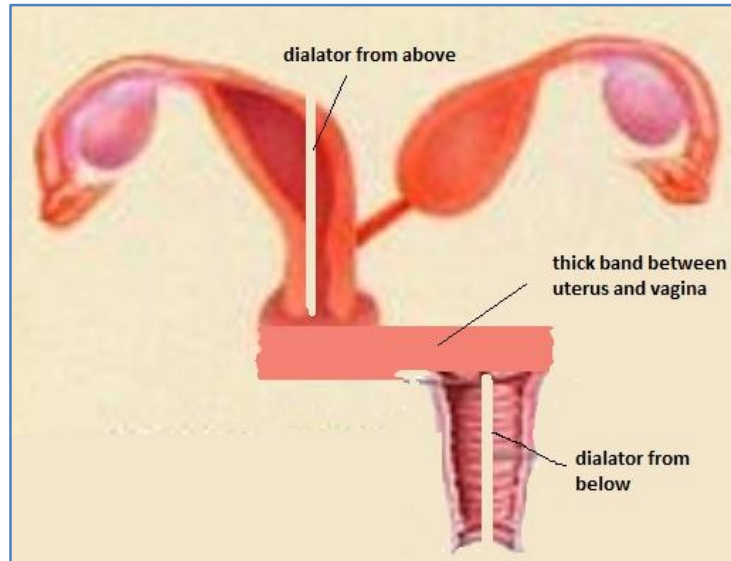
**Fig. 2: Left sided hypo plastic uterus non-communicating with right sided**

A thick band was found between the uteri and attempt was made from below to cut open the thick band and to communicate with the cervix of the vagina. However it was unsuccessful hence the right sided uterus was opened from above and dilators was passed from above into the cervix in the hope to open the blind vaginal pouch, and at the same time a dilator was inserted from the vagina in

## CASE REPORT

order to make two ends meet. But to our surprise, the indentation of the vaginal dilator was way too left sided away from the uterus and cervix, this made it impossible to establish a connection.

In addition it was also found that there was no hematometra or a hematocolpus and a very thin endometrial lining.



**Fig. 3: Non communicating band hemi uterus**

Hence the abdomen was closed only treating the pelvic endometrioma and leaving the uterus as it is. Cystoscopy was done which revealed no abnormality.

**DISCUSSION:** The complete, imperforate transverse vaginal septum is one of the most infrequent anomalies of female reproductive tract. The largest series reported by Lodi states an incidence of three cases in 90,000 patients.<sup>1</sup>

From this case apparently Sampson's theory<sup>2</sup> of the retrograde endometrial implantation due to her vaginal septum was corroborated.

Although reflux of menstrual fluid occurs in many, if not all, women, in endometriosis the refluxed cells implant in the pelvis, bleed in response to cyclic hormonal stimulation and increase in size along with progression of symptoms.<sup>3</sup>

Immune alterations may also contribute to the persistence of implants or endometriosis-associated infertility.<sup>4,5</sup>

GnRH Agonists are the agents when given, (e.g., leuprolide [Lupron], gosarelin [Zoladex]) inhibit the secretion of gonadotropin.<sup>6</sup>

But in retrospect, we wonder, if that was nature's way of preventing further endometriosis by creating a menopause like state, because further menstruation would pile up more endometrium into the peritoneum due to the septum. Since there was no hematometra along with low FSH and LH levels, it point towards the same perspective.

**CONCLUSION:** From this we conclude that her symptoms of cyclical dysmenorrhoea were due to her pelvic endometriosis which were treated during the laparotomy. She also had low FSH and LH level

## CASE REPORT

suggesting a menopausal like state with thin endometrial lining and no hematometra. Pt was put on lupride depot injections for the endometriosis.

### REFERENCES:

1. Lodi A. Contributo clinico statistic osullemal formazionidella vagina osservatenella clinica Obstetrica e Ginecologicadi Milano dal 1906 al 1950. Ann Obstet Gine. 1951; 73: 1246.
2. Sampson, J. A. (1927) Peritoneal endometriosis due to the menstrual semination of endometrial tissue into the peritoneal cavity. Am. J. Obstet.Gynecol., 14, 422-469.
3. Brosens IA. Endometriosis—a disease because it is characterized by bleeding. Am J Obstet Gynecol. 1997; 176: 263-7.
4. Gleicher N. Immune dysfunction—a potential target for treatment in endometriosis. Br J Obstet Gynaecol. 1993; 102(12 suppl): 4-7.
5. Martinez-Roman S, Balasch J, Creus M, Fabregues F, Carmona F, Vilella R, et al. Immunological factors in endometriosis-associated reproductive failure: studies in fertile and infertile women with and without endometriosis. Hum Reprod. 1997; 12: 1794-9.
6. Olive D, Schwartz LB. Endometriosis. N Engl J Med. 1993; 328: 1759-69.

### AUTHORS:

1. Swati Gawai
2. Sumit Paranjpe
3. Pradnya Changede
4. Niranjana Chavan

### PARTICULARS OF CONTRIBUTORS:

1. Registrar, Department of Obstetrics & Gynaecology, LTMMC & Sion Hospital, Mumbai.
2. Senior Registrar, Department of Obstetrics & Gynaecology, LTMMC & Sion Hospital, Mumbai.
3. Assistant Professor, Department of Obstetrics & Gynaecology, LTMMC & Sion Hospital, Mumbai.

### FINANCIAL OR OTHER

**COMPETING INTERESTS:** None

4. HOU, Department of Obstetrics & Gynaecology, LTMMC & Sion Hospital, Mumbai.

### NAME ADDRESS EMAIL ID OF THE CORRESPONDING AUTHOR:

Dr. Swati Gawai,  
Room No. 302, Old RMO,  
LTMMC & Sion, Mumbai.  
E-mail: gawai.swati@gmail.com

Date of Submission: 29/06/2015.  
Date of Peer Review: 30/06/2015.  
Date of Acceptance: 25/07/2015.  
Date of Publishing: 03/08/2015.