

PATHOLOGICAL SPECTRUM OF CONGENITAL ANOMALIES OF THE GASTROINTESTINAL TRACT- A 5 YEAR STUDY AT A PAEDIATRIC REFERRAL CENTRE.

M. Ramani¹, O. H. Radhika Krishna², K. Geeta³, K. Ramesh Reddy⁴, P. Sreenivas Reddy⁵, E. Soumya⁶, Puja Deshmukh⁷, Sandhya Rani⁸.

1. Professor, Department of Pathology, Niloufer Hospital.
2. Assistant Professor, Department of Pathology, Niloufer Hospital.
3. Assistant Professor, Department of Pathology, Niloufer Hospital.
4. Professor and Head of Department, Department of Paediatric surgery, Niloufer Hospital.
5. Professor, Department of Paediatric Surgery, Niloufer Hospital.
6. IIIrd year Under graduate, Department of Pathology, Osmania medical college.
7. Postgraduate, Department of Pathology, Niloufer Hospital.
8. Postgraduate, Department of Pathology, Niloufer Hospital.

CORRESPONDING AUTHOR:

Dr. M. Ramani,
Professor, Department of Pathology,
Niloufer Hospital for women and child health, Red hills,
Hyderabad, Andhra Pradesh.
Email- drmramani@sify.com

HOW TO CITE THIS ARTICLE:

M. Ramani, O. H. Radhika Krishna, K. Geeta, K. Ramesh Reddy, P. Sreenivas Reddy, E.Soumya, Puja Deshmukh, Sandhya Rani. " Pathological Spectrum of Congenital Anomalies of the Gastrointestinal Tract- a 5 year Study at a Paediatric Referral Centre". Journal of Evolution of Medical and Dental Sciences 2013; Vol2, Issue 25, June 24; Page: 4487-4496.

ABSTRACT: - INTRODUCTION: Congenital anomalies of gastrointestinal tract occur from oesophagus upto anorectum as a result of abnormal embryogenesis. Specific patterns of malformations of gastrointestinal tract include stenosis and atresia, duplications, abnormal rotation and fixation, abdominal defects and others associated with persistence of embryonic structures (e.g. Meckel's diverticulum), or abnormalities in its cellular components (e.g. nerves in Hirschsprung's disease). These disorders primarily result in symptoms of intestinal obstruction, effects on surrounding structures or of associated anomalies. Early diagnosis is therefore very vital.

AIM: To study the clinical presentation, radiological features, gross and histopathology of congenital anomalies of G.I.T. **MATERIAL AND METHODS:** Surgical specimens collected were sent to the department of pathology for gross and histopathological confirmation of diagnosis. The specimens were processed routinely and H & E stained slides studied. **RESULTS:** Out of 2996 specimens, 286 were found to be of congenital anomalies of G.I.T. With a sex ratio of 3:1 Hirschsprung's disease was commonest 50.34%, Omphalomesenteric duct remnants 16.78%, followed by intestinal atresia 10.13% **CONCLUSION:** Congenital anomalies of gastrointestinal tract are a cause of significant mortality and Morbidity in paediatric age group. Though radiodiagnosis is the preliminary diagnostic modality, gross and histopathological examinations are essential to confirm the diagnosis.

ORIGINAL ARTICLE

KEYWORDS: congenital anomalies of GIT, Hirschsprung's disease, Omphalomesenteric duct remnants, Meckel's diverticulum, duplications and cyst, intestinal atresia Meconium ileus.

INTRODUCTION: Congenital anomalies of the gastrointestinal tract are known to occur starting from oesophagus to ano rectum Alimentary tract abnormalities are a result of abnormal embryogenesis and they manifest during the neonatal period or later in life and are a cause of significant morbidity. Most common congenital anomalies of GIT are stenosis and atresia intestinal malrotation, duplication cysts ⁽⁸⁾, ano-rectal malformations, and abnormal neural Innervation. In Hirschsprung's disease ⁽³⁾, patients present with symptoms of intestinal obstruction usually diagnosed in the early life i.e. less than a year and based on clinical features (Picture 2). Diagnostic techniques involved are barium enema⁽²⁾, rectal biopsy and ano rectal manometry which is a gold standard for Hirschsprung's disease

Omphalomesenteric duct remnants: Omphalomesenteric Duct connects yolk sac with apex of intestinal loop and becomes obliterated by 10th week of embryonic life. In 2% of population it remains in various forms like vitelline cyst, heterotropic pancreas, Omphalomesenteric cyst etc. These anomalies are associated with intrauterine growth restrictions ⁽⁵⁾.

Meckel's diverticulum: Clinically, patients present with intestinal obstruction, peptic ulcer with bleeding, or diverticulitis ⁽⁶⁾, common in younger individuals, incidence is more in males. Intestinal Atresia accounts for about one third of all cases of neonatal intestinal obstruction ⁽⁷⁾, common in ileum and seen mostly in males. Clinically, patients present with symptoms depending on the level of GIT affected.

Enteric duplication cysts: Clinically, patients present with intestinal obstruction, pain, gastrointestinal haemorrhage, palpable abdominal mass ⁽⁶⁾ are commonly diagnosed in 1-5 years of age. **Meconium ileus:** Clinically patients present with manifestations of intestinal obstruction in first two days of life, commonly seen in male infants.

AIM OF THE STUDY: To study the clinical presentation radiological features, gross and histopathology of specimens of congenital anomalies of gastrointestinal tract received at department of pathology, of a Paediatric Referral hospital

MATERIALS AND METHODS: Out of 2992 pediatric surgical specimens received, over a period of 5 years from June 2004 to May 2009 in the department of Pathology of a Paediatric Referral centre in Andhra Pradesh, 286 cases(9.55%) were diagnosed as congenital anomalies of gastrointestinal tract both clinically and radiologically. The specimens sent to department of pathology for gross and histopathological confirmation were processed routinely and the H & E stained slides were studied.

RESULTS: Out of total 2992 surgical specimens, 286 specimens were found to be gastrointestinal system congenital anomalies i.e. 9.55% occurring in age group of 1-15 years, Male to Female ratio was 3:1 (Picture1)

Of total 286 congenital anomaly specimens received, Hirschsprung's disease was highest 144(50.34%), Omphalomesenteric duct remnants 48 (16.78%), followed by intestinal atresia, 29

ORIGINAL ARTICLE

cases (10.13%). Meconium Ileus 19(6.64%) Duplication Cysts 15(5.24%), Mesenteric Cysts 6(2.09%), Chylolymphatic Cysts 5(1.74%), Web/Stenosis 4(1.39%), Meconium Cyst 4 (1.04%),Malrotation 2 (0.7%), Heterotopic Pancreas 2(0.7%), Inspissated Bile Syndrome 2 (0.7%), Recto-vaginal Fistula2 (0.7%),Tracheo-oesophageal fistula (TOF)1(0.35%), TOF + Esophageal Atresia 1(0.35%), Anal Fistula 1(0.35%), Ectopia vesicae with Duplication Cysts 1(0.35%), and Imperforate Anus 1(0.35%). Age group and sex incidence of each anomaly is described (Table no.1.)

Hirschsprung's disease ⁽³⁾ (144/286, 50.34%) 114 were boys and 30 girls. Grossly, affected segment was distal non-dilated rectum or recto-sigmoid with a proximal dilated colon filled with inspissated faecal material due to anal canal pressure changes ⁽⁴⁾.Microscopy showed absence of mature ganglion cells with hypertrophied nerve bundles in sub mucosal and Myenteric plexuses.

Omphalomesenteric duct remnants (48/286, 16.78%) amongst these, Meckel's remnants had highest occurrence (Picture3). Meckel's diverticulum: arose from anti mesenteric border had a broad base, varied from 1 to 8 cm in length. Microscopically, wall consisted of all layers of bowel. Heterotopic tissues like pancreas were noticed in some cases.

Intestinal Atresia(29/286,10.13%) occurred in the form of diaphragm or septa occluding the lumen.(Picture 4) Microscopy showed entire intestinal wall included in septum, lumen replaced by a central core of granulation tissue with deposits of meconium, calcium, and foreign body giant cells.

Enteric Duplication Cysts (15/286, 5.24%) (Picture5) unilocular cysts lying in mesentery adherent to bowel, commonly seen in ileum, near ileocaecal valve and rare in duodenum ⁽⁸⁾.Lumen filled with bloody fluid or mucus. Microscopy, revealed mucosal lining of duplication cyst replicating some part of alimentary tract.

Meconium Ileus (19/286, 6.64%) (Picture6) terminal ileum relatively small and contained concretions of grey, inspissated meconium ⁽⁹⁾.Microscopy showed, distal ileal lumen filled with hypereosinophilic, focally calcified meconium. Intestinal glands dilated, V-shaped and plugged with hypereosinophilic secretions.

DISCUSSION: Congenital anomalies of the gastrointestinal tract occur from oesophagus to anorectum as A result of abnormal embryogenesis. Usually these cases have history of intrauterine Growth restriction (IUGR)⁽⁵⁾.Out of total paediatric specimens received,9.55%were Congenital anomalies of gastrointestinal tract. Among the 286 specimens, Hirschsprung's Disease accounted about 50.34%, omphalo-mesenteric duct remnants for 16.78% and Intestinal atresia 10.13%. In our study, Male: Female ratio was 3:1. When we compared with studies conducted in the Aseer Central hospital in Saudi Arabia , male: female ratio was 1.7: 1 (12).During a 6 year period, a total of 1386 Saudi infants were admitted into neonatal intensive care unit of Aseer Central Hospital. Of these, 12.4 % were confirmed to have congenital malformation of the gastrointestinal tract.172 newborn children presented with 174 anomalies of gastrointestinal tract. Malformations were imperforate anus(78 cases or 44.8%),trachea -oesophageal fistula/ Atresia(42 cases or 24.1%)and intestinal atresia(37 Cases or 21.3%).Other lesions included Hirschsprung's disease(14 cases or 8%)and Stenosis (2 pyloric and 1duodenal)(1.7%).Some patients had more than one defect Within the tract (1%) and multisystemic defects(23%).Overall fatality rate was(12%), Due largely to post-operative infection(75%) and multiple anomalies(25%).⁽¹²⁾ In a study conducted in Duke

ORIGINAL ARTICLE

University medical centre, Durham N.C., U.S.A. Sixty-two Percent of 34 patients had lesions such as upper gastrointestinal atresia and stenoses,

Intussusceptions and Hirschsprung's disease ⁽¹¹⁾. A retrospective study of 200 cases of congenital anomalies at the Jos University Teaching Hospital and Plateau State Specialist Hospital Jos – Nigeria between January 1998 and December 2005 showed that anomalies of the gastrointestinal system had the Highest incidence with 61 cases(30.5%).In their study, Omphalocele emerged as the Highest occurring congenital anomaly with 40% occurrence ,the other lesions were

Imperforate Anus 25%, gastrointestinal obstruction 16%,Hirschsprung's disease13.1% And Cleft Palate/lip had occurrence of 4.9 %⁽¹³⁾.

CONCLUSION: The embryologic and anatomic features of rotation anomalies, their clinical presentation And radiologic features are being presented with the suggestion that knowledge of this Information along with appreciation of the frequent association of malrotation with other Common congenital and acquired abnormalities, help to prevent devastating morbidity and Mortality of undiagnosed mid gut volvulus⁽¹¹⁾. This spectrum of congenital anomalies of the gastrointestinal tract shows that though radiodiagnosis is the preliminary diagnostic modality, gross and histopathological examination of the specimens plays a vital role in confirmation of diagnosis. Congenital anomalies of gastrointestinal tract are a cause of significant mortality and morbidity in paediatric age group especially in the case of Hirschsprung's disease which formed the major group in our study, histopathological examination ⁽¹⁰⁾ is the diagnostic modality to ensure early surgical management. Early diagnosis of these lesions decreases mortality and also lessens the burden on health care professionals and the parents of these children.

REFERENCES

1. Arun kumar Gupta et al. Imaging of Congenital Anomalies of GIT-(AIIMS) - Indian Journal of Pediatrics 2005;72(5):403-414.
2. Teresa Berrocal et al. Congenital Anomalies of the upper GIT- RadioGraphics 1999;19:855-87.
3. Hirschsprung'sdiseasewww.emedicine.com http://www.emedicinehealth.com/hirschsprung_s_disease-health/article_em.htm22.4.13.
4. J.O.N.Lawson, H.H. Nixon et al. Anal canal pressures in the diagnosis of Hirschsprung's disease -Journal of Pediatric Surgery; December 196;2(6); 544-552.
5. Dr Andras Jarnok, et al. Gastrointestinal malformations, associated congenital abnormalities and Intrauterine Growth Restriction–Journal of Pediatric Gastroenterology and Nutrition; April 2004;34(4);406-409.
6. Jayesh sagar, Vikas Kumar et al. Meckel's Diverticulum: a systemic review-Journal of the Royal Society of Medicine; October 2006; 99; 501-505.
7. T.R. Sai Prasad, M. Bajpai et al. Intestinal Atresia-The Indian Journal of Pediatrics; September 2000;67(9);671-678.
8. Enteric duplication cyst-www.pathologyoutlines.com22.4.13;9:45am

ORIGINAL ARTICLE

9. David Bryk et al. Meconium Ileus: demonstration of the meconium as on barium enema study – American Journal of Roentgenology; September 1965,9(1).
10. Essam A Elhalaby, Daniel HT eitelbaum, Arnold Coran, Kathleen P Heidelberger et al- Enterocolitis associated with Hirschsprung’s disease-Journal of Pediatric surgery; July 1995;30(7);1023-1027.
11. Howard C. Filston, Donald R. Kirks et al. Malrotation-The Ubiquitous Anomaly; Journal of Paediatrics Surgery; August 1981;16(4)-1;614–620.
12. Asindi A. Asindi, Saada Al -Daama, Mohammed S. Zayed, Yousef A. Fatinni et al Congenital malformation of the gastrointestinal tract in Aseer region, Saudi Arabia Saudi Medical Journal; 2002;23(9);1078-1082.
13. Ek were Okon Ek were, Rosie McNeil , Bob Paul Agim, Bamidele Jeminiwa, Olorunleke Oni 1 & Sunday Pam-A Retrospective Study of congenital anomalies presented at tertiary health facilities in Jos, Nigeria; JPCS October–December 2011;3;24-28

TABLE NO: 1

S.No	Congenital Anomaly	Age Range	Male	Female	Total	%
1	Hirschsprung’s Disease	0-12 yrs	114	30	144	50.34
2	Omphalomesenteric duct remnants	0-15 yrs	37	11	48	16.78
3	Intestinal Atresia	0-1 month	17	12	29	10.13
4	Meconium Ileus	0-1month	10	9	19	6.64
5	Duplication Cysts	0-10 yrs	8	7	15	5.24
6	Mesenteric Cysts	0-5 yrs	5	1	6	2.09
7	Chylolympatic Cysts	1-10 yrs	5	0	5	1.74
8	Web/Stenosis	0-8 yrs	3	1	4	1.39
9	Meconium Cyst	0-7 days	2	1	3	1.04
10	Malrotation	0-10 month	1	1	2	0.7
11	Heterotopic Pancreas	0-5 yrs	1	1	2	0.7
12	Inspissated Bile Syndrome	1-6 month	2	0	2	0.7
13	Recto-vaginal Fistula	1-5 yrs	0	2	2	0.7
14	Tracheo-esophageal fistula (TOF)	1yr	0	1	1	0.35
15	TOF + Esophageal Atresia	5 days	0	1	1	0.35
16	Anal Fistula	12 days	1	0	1	0.35
17	Ectopia vesicae with Duplication Cysts	7 Months	1	0	1	0.35
18	Imperforate Anus	1 day	1	0	1	0.35
Total	208	78	286			

ORIGINAL ARTICLE

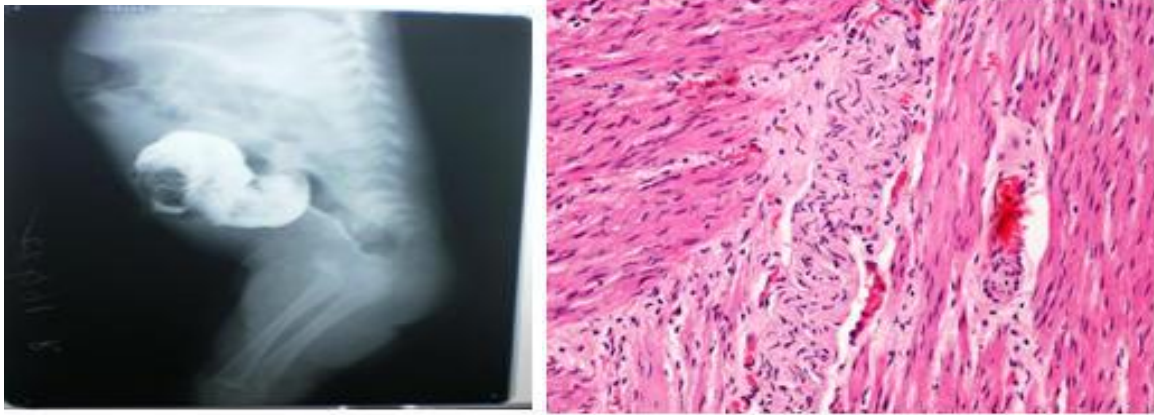


FIGURE1: a) Radiograph of barium enema showing proximally dilated segment,
b) Photomicrograph of Hirschsprung's disease showing hypertrophic nerve bundles. (H&E,40X).

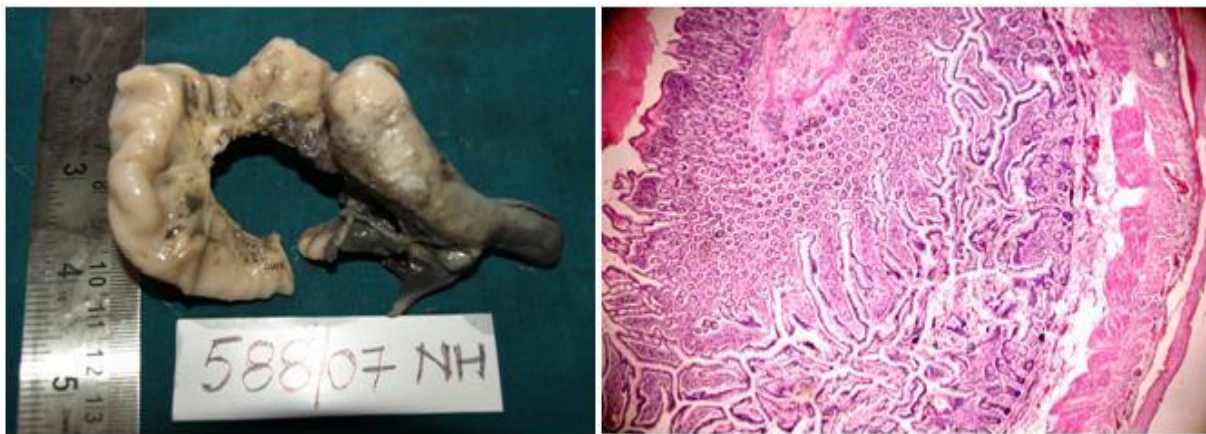


FIGURE2: a) Gross specimen of Meckel's diverticulum showing nodular tip.
b) Photomicrograph showing hypertrophied layers of the intestine (H&E, 10X).

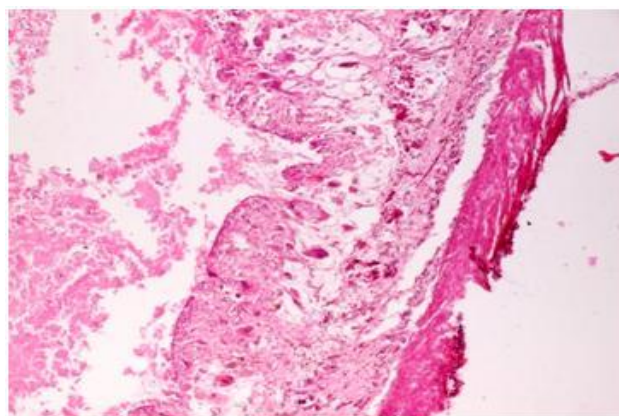


Figure3: Photomicrograph showing all the intestinal layers involved in septum (H&E, 10X).

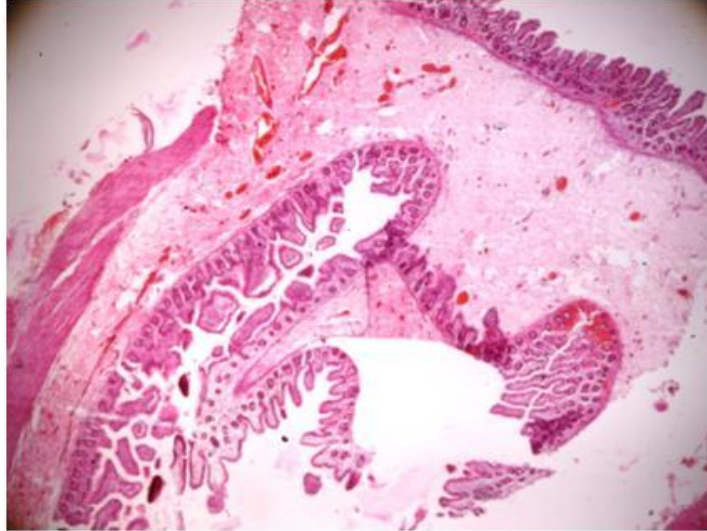
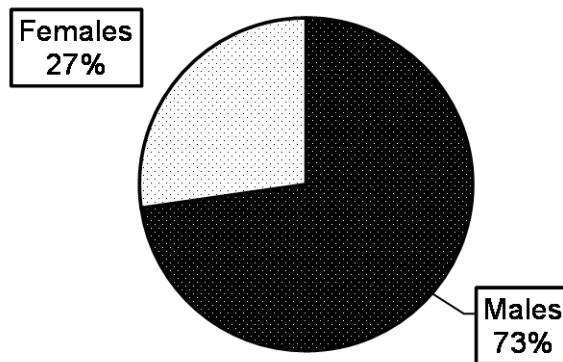


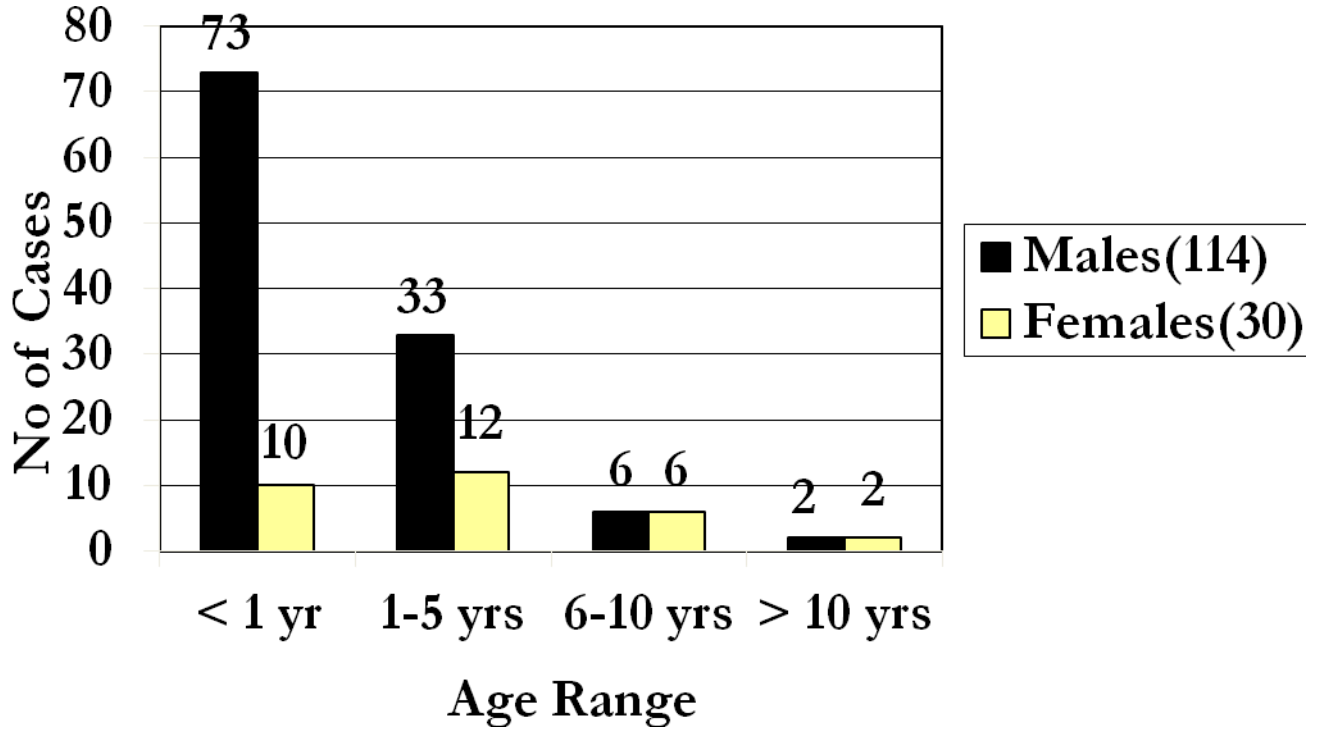
FIGURE4: Photomicrograph of duplication cyst showing replicated epithelium (H&E, 10X).

PICTURE1: Sex incidence of congenital anomalies of G.I.T.

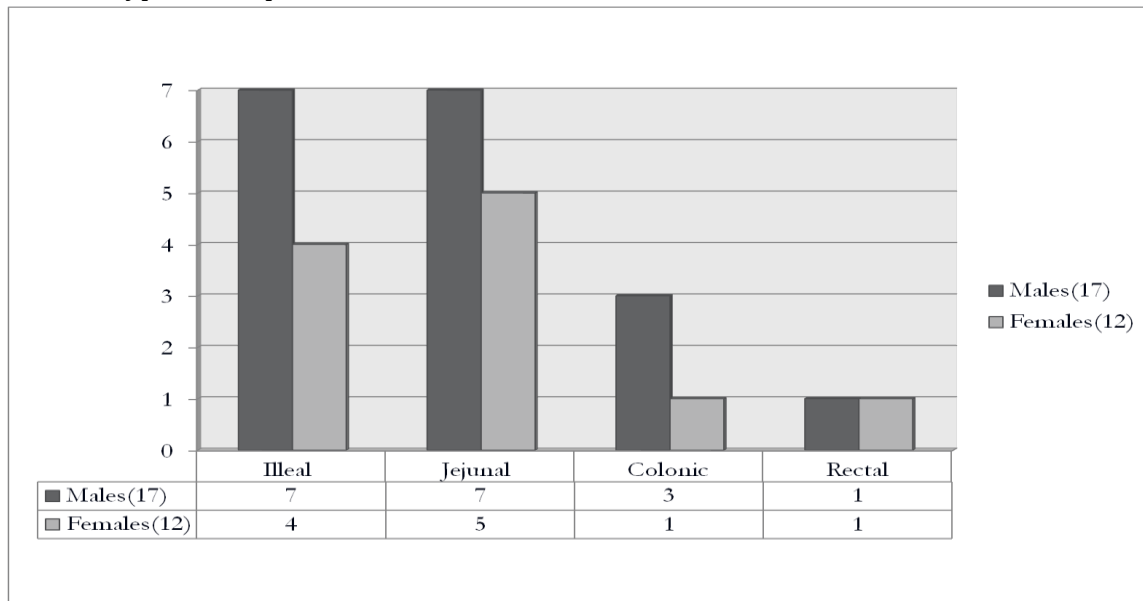


ORIGINAL ARTICLE

PICTURE 2: Distribution of Hirschsprung's disease in different age groups and in males and females.

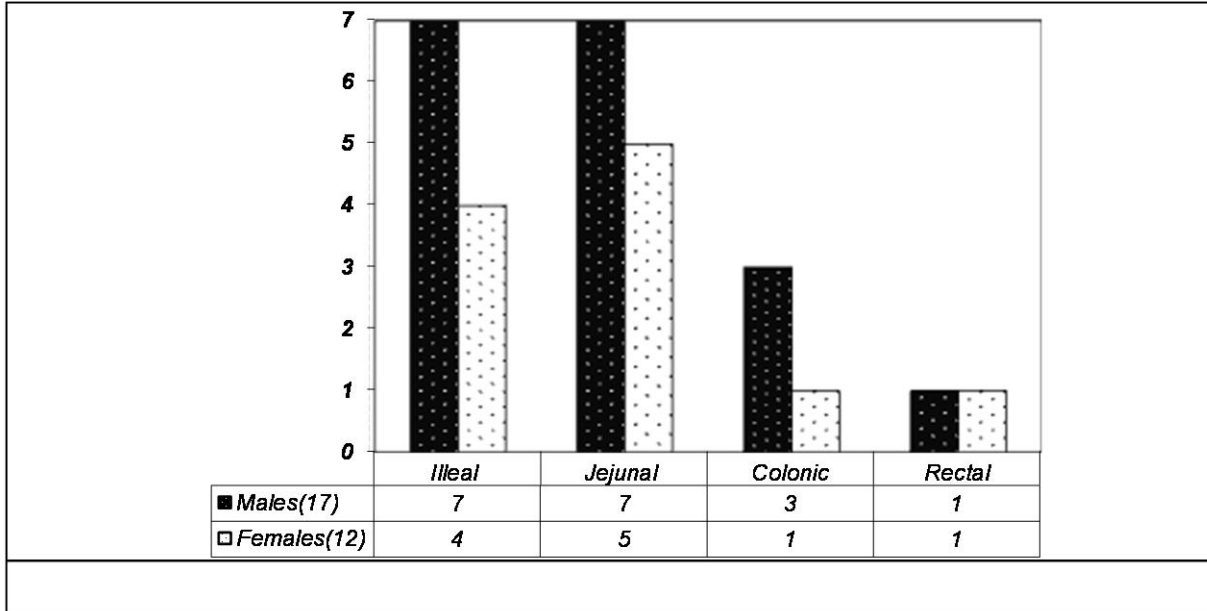


PICTURE 3: Types of Omphalomesenteric duct remnants in males and females

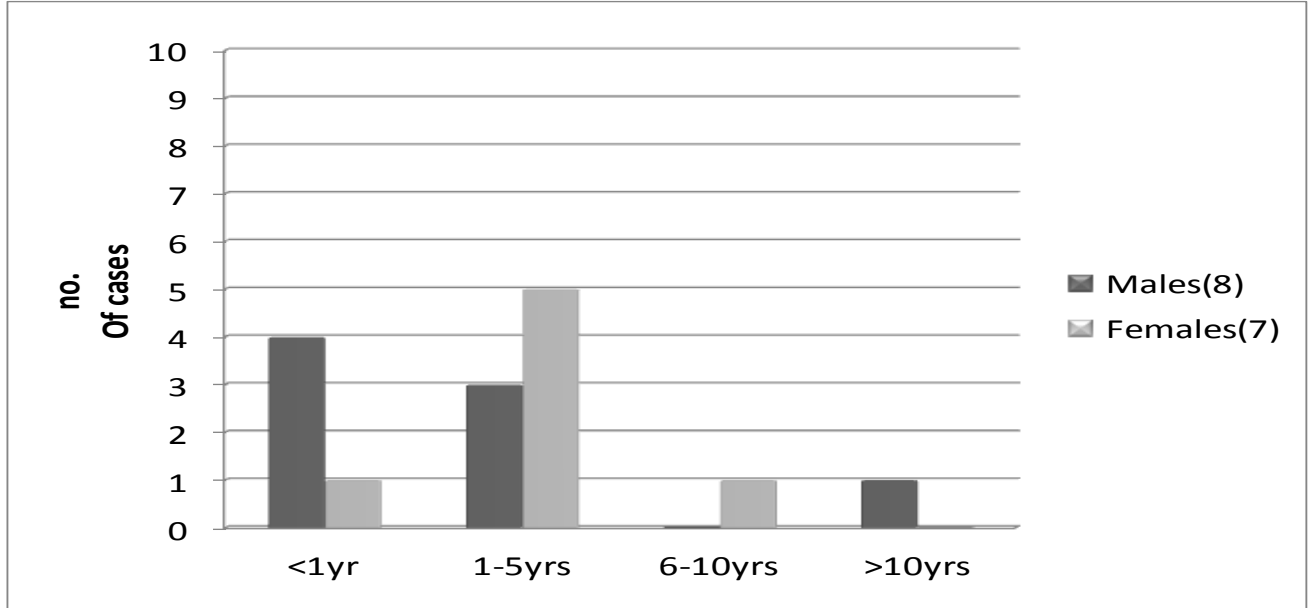


ORIGINAL ARTICLE

PICTURE 4: Occurrence of different types of Intestinal atresia in males and females



PICTURE 5: Enteric duplication cyst in different age groups.



PICTURE 6: Meconium ileus in males and females

