

DISTALLY BASED PERONEUS BREVIS MUSCLE FLAP FOR DISTAL LEG DEFECTS

Peddi Manjunath¹, Ramesha K.T², Smitha S Segu³, Jainath⁴, Shankarappa M⁵

HOW TO CITE THIS ARTICLE:

Peddi Manjunath, Ramesha KT, Smitha S Segu, Jainath, Shankarappa M. "Distally based peroneus brevis muscle flap for distal leg defects". Journal of Evolution of Medical and Dental Sciences 2013; Vol2, Issue 39, September 30; Page: 7541-7547.

AIMS: Distal leg defects are very difficult to cover because its structure its vicarious blood supply paucity of the muscles. Peroneus brevis muscle type 2 muscle long & slender to cover small & medium size defects. Prospective study conducted in Victoria hospital to cover the post traumatic distal leg defects. 20cases of distal leg defects exposing vital structure which require the flap cover. 16 patients are male, patients ranging from 18yrs to 65yrs. **RESULTS AND CONCLUSIONS:** 18 flaps survived. 2cases flap loss 2 cases graft loss. No functional deficit noted, less donor defect. Ideal flap for the small & medium size defects of distal leg.

KEY WORDS: Peroneus brevis, distal leg defects, muscle flap.

MESH TERMS: peroneus brevis, distal leg defects, muscle flap.

INTRODUCTION: Soft tissue management around the lower third of the leg and foot poses a considerable challenge, because tibia is subcutaneous bone with almost no muscles around its lower 1/3rd with tight skin and poor circulation hence it needs a full thickness skin cover.

Tendons, bone or hardware are frequently exposed because of the thinness of subcutaneous tissues, and mobile joint making skin grafting a poor option.

A durable flap with reliable vascularity, good arc of rotation, ease of dissection and minimum donor site morbidity is the most desired option for coverage of such defects.

The options for coverage of lower leg defects are fasciocutaneous flaps, distally based reverse sural artery, propeller flap and free flap procedures are relatively complex, time consuming, and require microsurgical expertise.

One excellent alternative within the reconstructive spectrum of the lower leg is the distally based peroneus brevis flap, which was first described by Mathes and Nahai and further characterized in detail by Eren et al and Yang et al. The muscle flap provides sufficient tissue for defect coverage of small and moderate defects; it has constant vascularity, and easy and quick elevation, with acceptable donor-site morbidity. We present our experience with 20 patients who were treated successfully without major complications, using the distally based peroneus brevis muscle flap for the coverage of soft and bony tissue defects over the lower one third of leg, the Achilles tendon, and the lateral and medial malleolus.

METHODS: From march 2010 to march 2013, 20 patients undergone distally based Peroneus brevis muscle flap for the distal leg defects. 16 patients are male, 4 patients are female. All cases are post traumatic exposing vital structures or hardware requiring the flap cover.

In cases where Fracture and joint stabilization were required are fixed before flap cover. Peroneus brevis is expandable type 2 Mathes & Nahai classification of muscle.

Surgical anatomy: Peroneus brevis muscle is deep muscle in the lateral compartment of leg. Originates from the junction of upper and middle third junction of the lateral surface of fibula descend closely to lateral surface of fibula, with Peroneus longus superficially and follow that surface as it spirals behind the triangular subcutaneous area of fibula to reach the posterior surface of lateral malleolus, tendon pass under the retinaculum to get inserted to the base of the fifth metatarsal. Nerve supply from superficial peroneal nerve.

It is described as both type II and type IV muscle based on its vasculature. Proximally, the neurovascular bundle enters the muscle within 2-4 cm of the upper end of the muscle. Several branches from the peroneal vessels pierce the posterior septum and supply the muscle. A constant perforator is noted by the peroneal artery at 5-6cm above the lateral malleoli. It receives a few branches from the anterior tibial artery also.

Surgical technique: All the surgeries are done under regional block with tourniquet. The foot is rested on sand bag, knee flexed 60⁰-70⁰. Skin markings are made, perforator marked by hand held Doppler. Incision 2cm posterior to the fibula vertical incision extending from middle one third to 7cm above the lateral malleoli. Deep fascia incised, superficial peroneal nerve isolated and preserved. Identified the peroneus longus and peroneus brevis muscle at the junction of middle one third and lower one third, long tendon peroneus longus and muscular portion of peroneus brevis. Peroneus longus retracted anteriorly. Brevis muscle dissected from the origin by sharp dissection divided from the fibula. Muscle dissected till 7cm from lateral malleoli. Finally muscle is used to cover the defect by tunneling subcutaneously or over the wound.

RESULTS: Reconstruction of the lower leg and foot continues to be one of the most challenging tasks for the reconstructive plastic surgeon. An unreliable lower limb subdermal plexus translates to notoriously poor wound healing using cutaneous flaps.

Following the developments in flap surgery, pedicled fasciocutaneous flaps and free flaps have been used. The introduction of distally based peroneus brevis flap provides reliable and effective method to cover skin defects of distal leg, foot and ankle.

There are total of 20 patients, out of which 16 are male and 4 are female patient. 14 patients had lower third leg defects with exposing the tibia, 3 patients had defect over ankle joint. 3 patients had tendo achilles exposed. The average time taken for the surgery was 76minites. The defect size covered range from 2x1 cm to 6x3 cm.

We had complete loss of flap over critical area in two cases. Loss of skin graft in two cases, these two cases later covered with skin graft. There is no functional deficit noted in the leg. Minimal donor morbidity only scar on the lateral aspect of the leg.

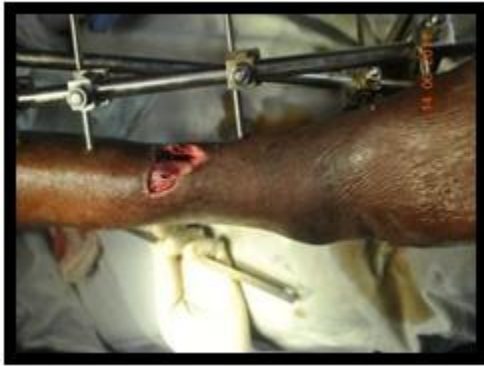

Fig. 1

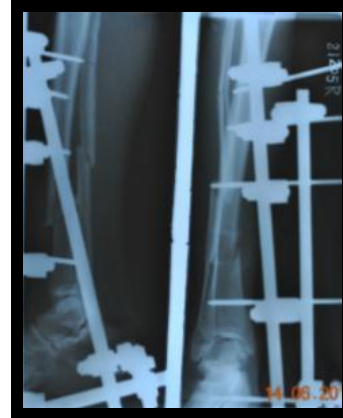


Fig. 2

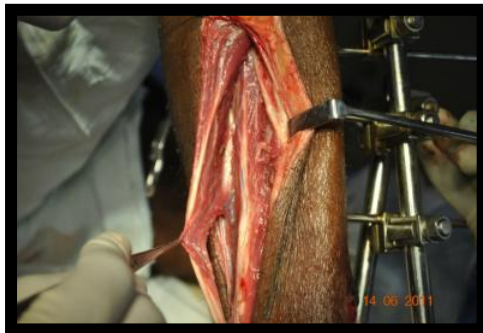

Fig. 3

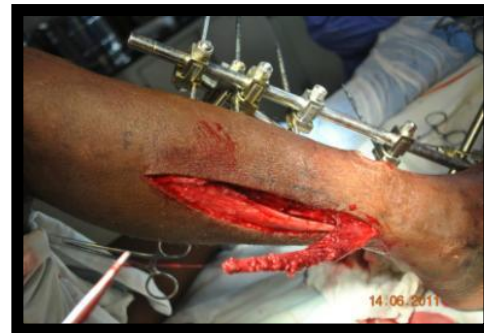

Fig. 4

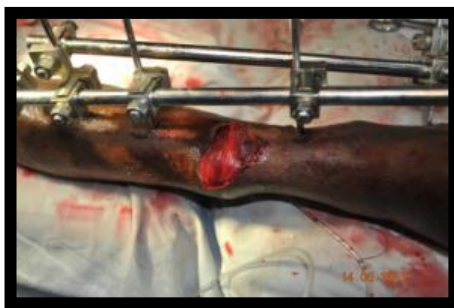

Fig. 5

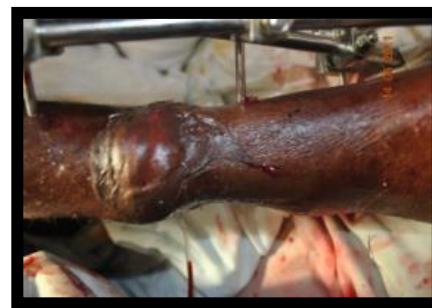

Fig. 6

Case 1: post traumatic lower third leg defect exposing tibia bone.
X - Ray shows both bone fracture Incision & exposure of peroneus muscle Peroneus brevis muscle dissected Covered over the defect Skin graft placed Donor area.

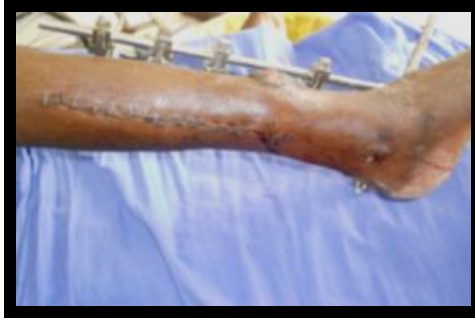
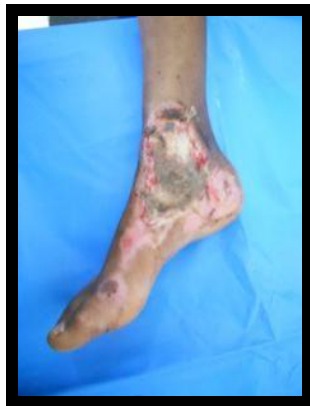
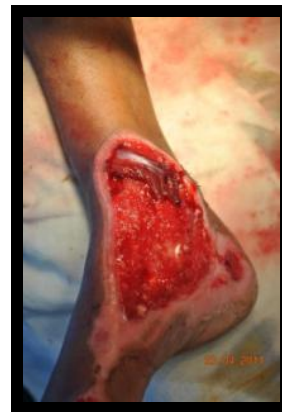Fig. 7

Case: 7

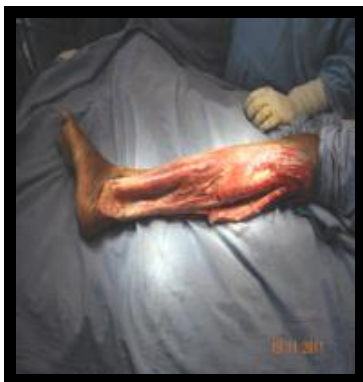

Post traumatic medial malleoli exposed



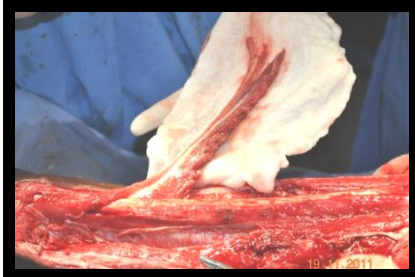Peroneus brevis muscle flap covering the malleoli

Case: 9

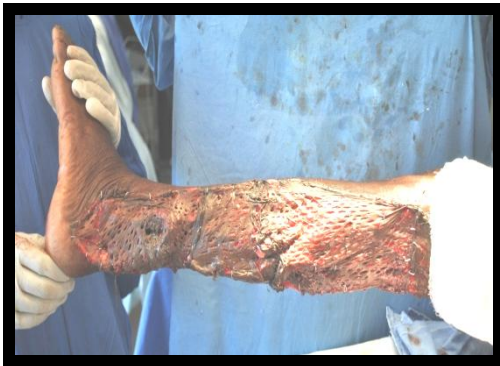
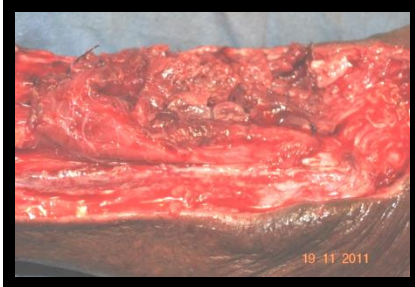
Post traumatic degloving injury of lateral side of leg with exposing the tendo achilles tendon

ORIGINAL ARTICLE



Peroneus brevis muscle flap to cover tendo achilles



Raw area covered with meshed skin graft

DISCUSSION: However, muscle flaps remain often the first choice, when dealing with bone infections associated with osteomyelitis, soft tissue infections, and cavities. Since common local proximal-based muscle transposition flaps have difficulty reaching the heel and the ankle region, these defects are normally treated by free tissue transfer because free muscle flaps provide reliable single-stage coverage. However, there are some disadvantages which are associated with the application of free flaps: the donor-site morbidity, increased operation time, use of a major vessel of the leg, and the necessity of microsurgical expertise. An alternative muscle flap for defect coverage of the lower leg and ankle is the distally based Peroneus brevis flap. This flap was first described in 1997 by Mathes and Nahai. Details on the principle to elevate the flap for wound coverage in the lower leg have been published by Eren et al. It has many advantages in comparison to other reconstructive options. The major advantages are a quick and safe surgery, reliable soft tissue coverage of bone and tendons, with muscle tissue and preservation of major arteries of the leg. Besides, donor-site morbidity is negligible because the preserved peroneus longus muscle will maintain the function of plantar flexion and foot eversion. Eren et al concluded that the blood supply of the flap is provided by segmental branches of the peroneal artery, with the most distal perforator being present approximately 3 finger breadths proximal to the tip of the fibula and in addition by retrograde perfusion from the posterior tibial artery. These observations are consistent

ORIGINAL ARTICLE

with the findings of the authors. In all our cases, the main distal vascular pedicle could be mapped approximately 5-6 cm proximal of the lateral malleolus. Yang et al¹ showed recently in a cadaver dissection study on 6 muscle specimens an average distance of the distal pedicle from the tip of the lateral malleolus from 3 to 6 cm (mean 4.25 cm). They recommended preserving the attachment of the muscle to the distal 6 cm of the fibula to assure the blood supply and to increase flap reliability.

Although we used the peroneus brevis flap in this series for defect coverage of the lateral malleolus, Achilles tendon, and lower third of tibia and leg. Patients displayed severe vascular risk factors such as heavy smoking, arterial hypertension, diabetes, or peripheral vascular disease. We observed necrosis of the distal part of the flap only in 2 patients with exposing critical area later covered with other flap. Two patients had skin graft loss later regrafted over the muscle

CONCLUSION: The distally based Peroneus muscle flap is a versatile and reliable flap for the coverage of soft tissue defects of the distal lower extremity. The procedure is done as a single stage; the dissection is easy with a short operating time and minimal donor morbidity.

REFERENCES:

1. Mathes SJ, Nahai F. *Reconstructive Surgery: Principles, Anatomy and Technique*. New York: Churchill-Livingstone; 1997
2. Eren S, Ghofrani A, Reifenrath M. The distally pedicled peroneus brevis muscle flap: a new flap for the lower leg. *Plast Reconstr Surg*. 2001; 107:1443-1448.
3. Yang YL, Lin TM, Lee SS, et al. The distally pedicled peroneus brevis muscle flap anatomic studies and clinical applications. *J Foot Ankle Surg*. 2005;44:259-264
4. Mathes SJ, Nahai F. Classification of the vascular anatomy of muscles: experimental and clinical correlation. *Plast Reconstr Surg*. 1981; 67:177-187.
5. Lyle WG, Colborn GL. The peroneus brevis muscle flap for lower leg defects. *Ann Plast Surg*. 2000; 44:158-162
6. Bajantri B, Bharthi R, Ramkumar S, Latheef L, Dhane S, Sabapathy SR. Experience with peroneous brevis muscle flaps for reconstruction of distal leg and ankle defects. *Indian J Plast surg* 2013;46:48-54
7. Arnold PG, Yugueros P, Hanssen AD. Muscle flaps in osteomyelitis of the lower extremity: a 20-year account. *Plast Reconstr Surg*. 1999; 104: 107-110.
8. Kneser U, Bach AD, Polykandriotis E, et al. Delayed reverse sural flap for staged reconstruction of the foot and lower leg. *Plast Reconstr Surg*. 2005; 116:1910-1917.
9. Hallock GG. Utility of both muscle and fascia flaps in severe lower extremity trauma. *J Trauma*. 2000; 48:913-917.
10. Jackson IT, Scheker L. Muscle and myo cutaneous flaps on the lower limb. *Injury*. 1982; 13:324-330.
11. Wells MD, Bowen CV, Manktelow RT, et al. Lower extremity free flaps: a review. *Can Surg*. 1996; 39:233-239.
12. Attinger C, Cooper P. Soft tissue reconstruction for calcaneal fractures or osteomyelitis. *Orthop Clin North Am*. 2001; 32:135-170.
13. Ayyappan T, Chadha A. Super sural neuro fasciocutaneous flaps in acute traumatic heel reconstructions. *Plast Reconstr Surg*. 2002; 109:2307-2313.

ORIGINAL ARTICLE

14. Hsieh CH, Liang CC, Kueh NS, et al. Distally based sural island flap for the reconstruction of a large soft tissue defect in an open tibial fracture with occluded anterior and posterior tibial arteries-a case report. Br J Plast Surg. 2005; 58:112-115.
15. Greant P. The distally based superficial sural flap for reconstruction of the lower leg and foot. Br J Plast Surg. 1997; 50: 295-296.
16. Smith IM, Austin OM, Batchelor AG. The treatment of chronic osteomyelitis: a 10 year audit. Br J Plast Surg. 2005; 59:11-15.

AUTHORS:

1. Peddi Manjunath
2. Ramesha K.T.
3. Smitha S Segu
4. Jainath
5. Shankarappa M.

PARTICULARS OF CONTRIBUTORS:

1. Assistant Professor, Department of Plastic Surgery, Victoria Hospital, BMCRI, Bangalore.
2. Associate Professor, Department of Plastic Surgery, Victoria Hospital, BMCRI, Bangalore.
3. Associate Professor, Department of Plastic Surgery, Victoria Hospital, BMCRI, Bangalore.
4. Assistant Professor, Department of Plastic Surgery, Victoria Hospital, BMCRI, Bangalore.

5. Professor, Department of Plastic Surgery, Victoria Hospital, BMCRI, Bangalore.

NAME ADDRESS EMAIL ID OF THE CORRESPONDING AUTHOR:

Dr. Peddi Manjunath,
MF 33-11,
Nandini Layout,
Bangalore - 560096.
Email- peddim@gmail.com

Date of Submission: 23/09/2013.
Date of Peer Review: 24/09/2013.
Date of Acceptance: 25/09/2013.
Date of Publishing: 27/09/2013.