

OSSIFICATION OF TRANSVERSE SCAPULAR LIGAMENT IN NORTH INDIAN POPULATION

Md. Jawed Akhtar¹, Premjeet Kumar Madhukar², Nafees Fatima³, Avanish Kumar⁴, Binod Kumar⁵, Rajiv Ranjan Sinha⁶, Vinod Kumar⁷

HOW TO CITE THIS ARTICLE:

Md. Jawed Akhtar, Premjeet Kumar Madhukar, Nafees Fatima, Avanish Kumar, Binod Kumar, Rajiv Ranjan Sinha, Vinod Kumar. "Ossification of Transverse Scapular Ligament in North Indian Population". Journal of Evolution of Medical and Dental Sciences 2014; Vol. 3, Issue 63, November 20; Page: 13884-13892, DOI: 10.14260/jemds/2014/3856

ABSTRACT: BACKGROUND: Suprascapular nerve may be compressed anywhere along its course but commonly compressed at the level of suprascapular notch and spinoglenoid notch. Supra-scapular notch is bridged by superior transverse scapular ligament and changes into a foramen which provides passage for suprascapular nerve. When it is completely ossified it becomes suprascapular foramen in dry scapulae. Overhead abduction of shoulder joint exerts traction on the suprascapular nerve, which leads to its compression against superior border of scapula. The risk of suprascapular nerve entrapment increases when the superior transverse scapular ligament gets completely ossified. **AIM & OBJECTIVE:** To study the incidence of complete and partial ossification of suprascapular ligament in north Indian population & compare it with incidence among various races of world. **MATERIALS AND METHODS:** A total of 224 dry scapulae (Right-110, Left-114) are analyzed to see the complete or partial ossification of suprascapular ligament on superior border of scapula. **RESULTS:** Scapulae with completely ossified STSL are found in 28 among 224 scapulae (12.5%), in which 18 (8.04%) belongs to right side & 10 (4.46%) to left side, while scapulae with partially ossified STSL are found in 49 among 224 scapulae (21.87%), in which 32 (14.28%) belongs to right side & 17 (7.59%) to left side. The completely and partially ossified STSL both are more common in right side as compared to left side. **CONCLUSION:** Present study demonstrates that suprascapular foramen which is the result of complete ossification of superior transverse scapular ligament, which is not extremely rare in North Indian population. So, the anatomical knowledge about this foramen helps the practicing physicians & surgeons in early diagnosis of suprascapular nerve entrapment syndrome.

KEYWORDS: Scapula, Suprascapular notch, Transverse scapular ligament, Suprascapular nerve, Nerve entrapment syndrome.

INTRODUCTION: The scapula which is commonly known as shoulder blade is a flat triangular bone that present on posterolateral thoracic wall, against the second to seventh ribs. It has two surfaces ventral & dorsal. The concave dorsal surface divided into a smaller supraspinous fossa and larger infrascapular fossa. The convex ventral surface has also a fossa named subscapular fossa. It has three borders namely medial, lateral and superior which also forms three angles i.e. lateral, superior and inferior.

Among all these three borders, superior border is thinnest and shortest.^[1] The superior border has a deficient portion near the base of coracoid process which is known as suprascapular notch. A foramen is formed after bridging of this notch by a strong fibrous band like structure namely suprascapular ligament or transverse scapular ligament. The suprascapular nerve, a branch from

ORIGINAL ARTICLE

superior trunk of brachial plexus, passes through this foramen and supplies the supraspinatus & infraspinatus muscles while the suprascapular vessels goes backward above this ligament.

Sometimes this ligament is ossified.^[2] There are also so many variations seen in superior transverse scapular ligament like multiple bands and calcification,^[3] bifurcation,^[4] trifurcation,^[5] and hypertrophy.^[6] In some animals, this suprascapular notch is always bridges by bone in place of ligament.^[7] Overhead abduction of shoulder joint causes traction on this suprascapular nerve, which may compress it against superior border of scapula. The common site of compression of suprascapular nerve is at the suprascapular notch or at the spinoglenoid notch in nerve entrapment syndrome, an acquired neuropathy.

This syndrome is characterized by vague pain on the posterolateral aspect of shoulder and atrophy of supraspinatus & infraspinatus muscles. The patients also complain about weakness of external rotation and abduction of arm. This compression becomes more pronounced when suprascapular ligament is completely or partial ossified. Hence, the clinician always kept in mind about possibility of different variations in course of the nerve in patients of suprascapular nerve entrapment syndrome. In 1959, Kopell and Thompson first of all describe this syndrome.^[8] Here, we study the incidence of complete and partial ossification of suprascapular ligament in north Indian population & compare it with incidence among various races of world.

MATERIALS AND METHODS: The present study has been carried out on 224 (Right-110, Left-114) dried human scapulae of unknown sex & age, which are obtained from Department of Anatomy & Department of Forensic Medicine & Toxicology of Indira Gandhi Institute of Medical Sciences (Patna, Bihar, India), Lord Buddha Koshi Medical College (Saharsa, Bihar, India), F. I. Maulana Ali Mian Medical College (Unnao, Uttar Pradesh, India), Patna Medical College (Patna, Bihar, India), Nalanda Medical College (Patna, Bihar, India), after obtaining consents and permission for the study from heads of the institutes and anatomy department. Each scapula is observed carefully for complete or incomplete ossification of suprascapular ligament on superior border of scapula. Scapula having marked deformities and damaged superior border are excluded from the study. Representative photographs of absence of suprascapular notch are taken using a digital camera (Nikon 12 Megapixels).

RESULTS: Scapulae with completely ossified STSL are found in 28 among 224 scapulae (12.5%), in which 18 belongs to right side & 10 to left side, while scapulae with incompletely ossified STSL are found in 49 among 224 scapulae (21.87%), in which 32 belongs to right side & 17 to left side. The completely and incompletely ossified STSL both are more common in right side as compared to left side. [Table-1 & Figure- 1, 4, 5, 6, 7 & 8]

Serial No.	Right side	Left side	Total
1. No. of scapula with completely ossified STSL	18 (8.04%)	10(4.46%)	28(12.5%)
2. No. of scapula with incompletely ossified STSL	32 (14.28%)	17(7.59%)	49(21.87%)
3. No. of scapula without ossified STSL	60 (26.79%)	87(38.84%)	147(65.63%)
Total	110(49.11%)	114(50.89%)	224(100%)

TABLE-1: Sidewise allocation of completely or partially ossified STSL

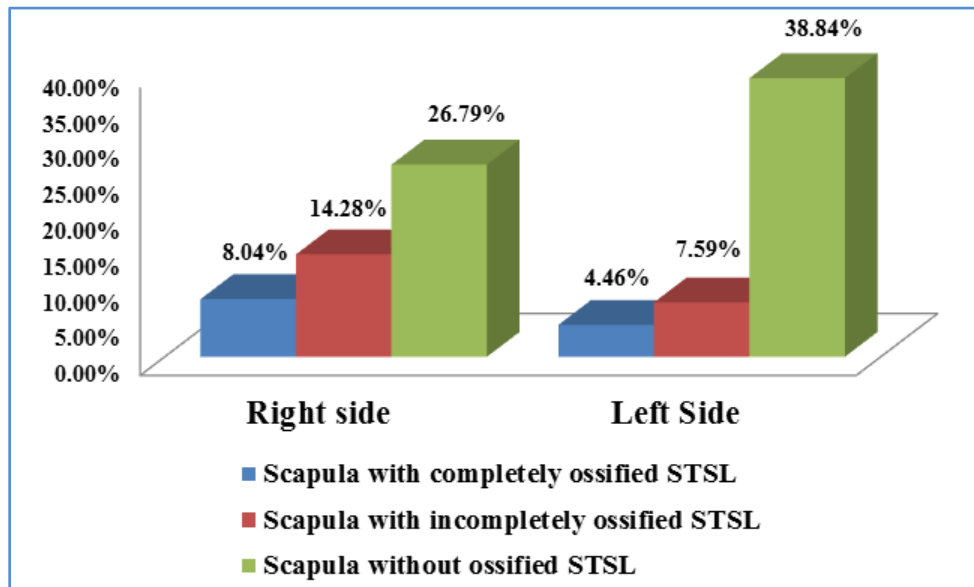


Fig. 1: Distribution of completely & partially ossified STSL in right & left side scapula

DISCUSSION: The ossification of suprascapular ligament is multifactorial and from the literatures we found that its incidence varies in different populations of world as shown in Table no. – 02 & 03. In present study, we found 12.5% incidence of completely ossified STSL which is close to findings of Jadhav et al^[9] (10.57%). Silva et al^[10] found the incidence of completely ossified STSL 30.76% in Brazilian population which is very high as compared to our study (12.5%). In some parts of world its incidence is very rare e.g. in Alaskan Eskimos - 0.3%, Native American - 2.1% to 2.9%.^[6] In Nigeria, Osuagwu et al^[11] found a case of completely ossified STSL & Khan^[7] & Das et al^[12] also found a similar case in India. In literature, we found that in Indian population the incidence of completely ossified STSL varies from 1.93% to 19.44%.

We also found 21.87% incidence of partially ossified STSL in our study which is more than findings of Edelson et al^[13] (8.1%), Mahto R K et al^[14] (10.66%), Dunkengrun et al^[3] (12%), Ticker et al^[5] (18%) & Silva et al^[10] (19.6%), but less than Polguy et al^[15] (23.3%) & Mistry P et al^[16] (25%). But, many authors like Jadhav et al,^[9] Kalpana T et al,^[17] Natsis et al,^[18] Sinkeet et al^[19] did not studied about partial ossification of STSL. This bony bridges are more common in Caucasian male.^[6] A familial case of calcification of STSL in both father and son found during study of Cohen et al,^[4] causing entrapment syndrome of suprascapular nerve indicates the genetic basis of ossification. The thickness of ossified STSL in Indian population is 2.8 ± 0.96 mm as found in study of Mistry et al.^[16] Sandow & Ilic^[20] explained that suprascapular nerve compression is more common in volleyball players due to some specific type of movements likes abduction associated with lateral (external) rotation.

ORIGINAL ARTICLE

There are six different types of suprascapular notch according to Rangachary et al.,^[21,22] in which type VI is described as scapula with completely ossified STSL forming the foramen. While, Natsis et al^[18] classified the suprascapular notch into only five types, in which type IV is described as scapula with bony foramen.

De Mulder et al^[23] & Warner et al^[24] explained in their study that during open surgical procedures, the distance between margin of the glenoid cavity and suprascapular notch is very critical and it needs dissection of the posterior shoulder joint. A safe zone is explained by them to avoid damage to the suprascapular nerve during the surgeries around this area.^[25] These distances are 1.4 cm from posterior border of glenoid just at the base of spine of scapula & 2.3 cm from glenoid just at the upper rim of glenoid. Therefore, the surgeons aware about this safe zone during surgical procedures at shoulder joint, to avoid damage of the nerve.

Polguy M^[26] found bifid superior transverse scapular ligament in 3.1% population, while Ticker JB et al^[5] found trifid superior transverse scapular ligament in only 3% population. There are five types of superior transverse scapular ligament as explained by Bayramoglu et al.^[27] The first is fan shaped, which is the most common type, the second type has an additional anterior coracoscapular ligament. The third type has two parts i.e. anterior & posterior and in fourth type the ligament is calcified, which is least common type. Wang HJ^[28] explained a scapula with double suprascapular foramen in Chinese population.

The motor supply of supra & infraspinatus muscles comes from suprascapular nerve, but this nerve does not supply the adjoining skin. So, any irritations in the nerve fibers causes deep pain, which is not well localized. When the patient comes to a clinician with his complains, the muscles atrophy get started.^[8] For early & correct diagnosis, every clinician must have detail anatomical knowledge about the course of suprascapular nerve & all possible sites of its compression. It is mainly compressed at two sites: (a) At the suprascapular notch & (b) At the base of scapular spine.

Thompson et al^[8] explained that its compression against superior transverse scapular ligament occurs mainly during horizontal adduction & abduction of shoulder joint. This compression may be more when superior transeverse scapular ligament becomes ossified.^[7] The suprascapular nerve entrapment syndrome presents with initial symptoms of burning sensations, numbness & weakness in the hand, which later on present only weakness of abduction and external rotation of shoulder joint as explained by Black KP & Lombardo JA.^[29] The X-ray, CT scan, electromyographic studies (EMG), nerve conduction velocity test (NCV), MRI & arthrography are some recent investigation techniques which helps in correct diagnosis of nerve entrapment.

Sr. No.	Population	Author (year of study)	No. of scapula studied	Incidence (%)
1.	Finnish	Kajava et al ^[30] (1924)	133	1.5%
2.	French	Vallois HV ^[31] (1925)	200	6.5%
3.	American	Edelson et al ^[13] (1995)	1000	3.7%
4.	American	Ticker et al ^[5] (1998)	79	5%
5.	American	Dunkengrun et al ^[3] (2003)	623	5%
6.	Nigerian	Osuagwu et al ^[11] (2005)	A case report	
7.	German	Nastis et al ^[18] (2007)	423	7.3%
8.	Brazilian	Silva et al ^[10] (2007)	221	30.76%
9.	Kenyan	Sinkeet et al ^[19] (2010)	138	2.9%

ORIGINAL ARTICLE

10.	Poland	Polguy et al ^[15] (2011)	86	7%
11.	Chinese	Wang et al ^[28] (2011)	295	1.36%
12.	Indian	Present study (2014)	224	12.5%

Table 2: Comparison of Incidences of completely ossified STSL in different population of world

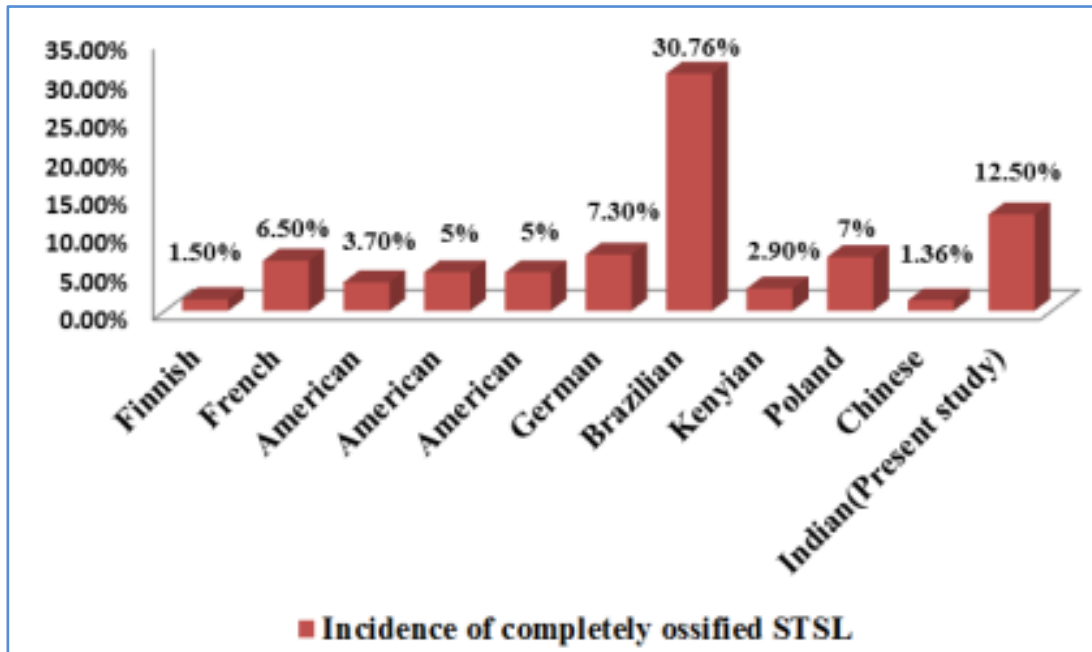


Fig. 2: Comparison of Incidence of completely ossified STSL in different parts of world

Sr. No.	Population	Author (year of study)	No. of scapula studied	Incidence (%)
1.	Indian	Khan M A ^[7] (2006)	A case report	
2.	Indian	Das et al ^[12] (2007)	A case report	
3.	Indian	Jadhav et al ^[9] (2012)	350	10.57%
4.	Indian	Muralidhar et al ^[32] (2013)	104	1.93%
5.	Indian	Kalpana T et al ^[17] (2013)	100	2%
6.	Indian	Pragna P et al ^[33] (2013)	80	3.75%
7.	Indian	Vashudha T K ^[34] (2013)	115	4.34%
8.	Indian	Mahto R K et al ^[14] (2013)	122	4.92%
9.	Indian	Mistry P et al ^[16] (2013)	180	19.44%
10.	Indian	Udatree et al ^[35] (2014)	42	9.5%
11.	Indian	Present study (2014)	224	12.5%

Table 3: Comparison of Incidences of completely ossified STSL in Indian population

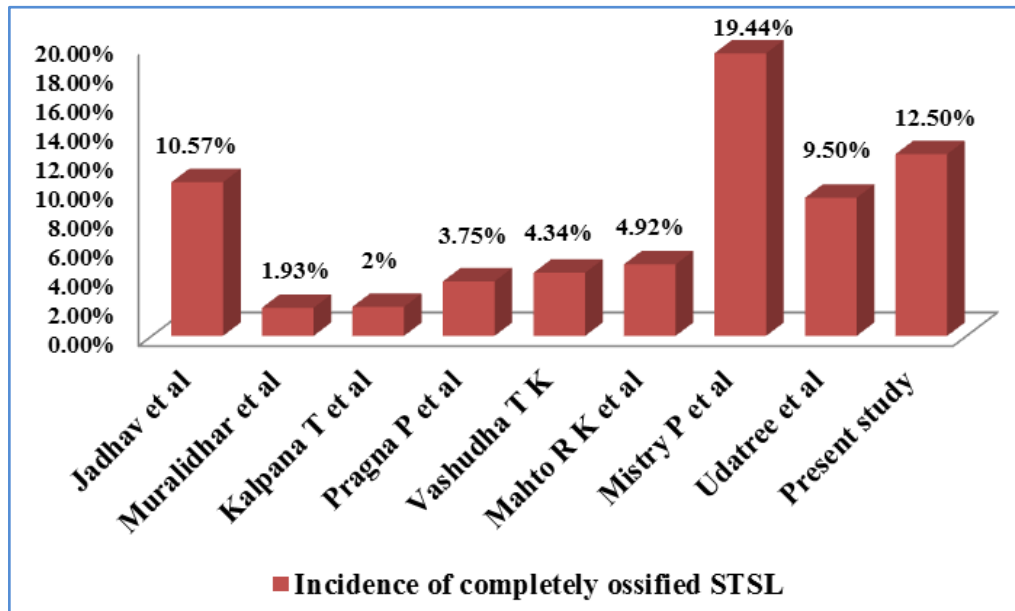


Fig. 3: Comparison of Incidence of completely ossified STSL in Indian population

CONCLUSION: Present study showed 12.5% incidence of complete ossification of STSL in north Indian population, which indicates it is not so rare as we found in different literatures. So, this anatomical information should always be taken into consideration during surgical or arthroscopic shoulder procedures & also in case of treatment of painful shoulder. Its knowledge helps the practicing surgeons in avoiding iatrogenic suprascapular nerve injury in surgical procedures around this region. Since the present study is based on limited number of dry scapulae in a small geographical area, so there is need of more clinical, radiological and cadaveric studies on large population across the world. [STSL--Superior transverse scapular ligament]

REFERENCES:

1. Moore KL, Dalley AF. Clinical oriented Anatomy. 5th edition, Williams & Wilkins Lippincott, 2006. pp 730-732.
2. Standring S, "Pectoral girdle and upper limb" in Gray's Anatomy: The Anatomical Basis of Clinical Practices, Johnson D & Collins P., Eds. Churchill Livingstone, New York, USA, 40th ed, 2008. pp. 793-821.
3. Dunkelgrun M, Iesaka K, Park SS, Kummer FJ, and Zuckerman JD. Interobserver reliability and intraobserver reproducibility in suprascapular notch typing. Bull Hosp Joint Dis. 2003; 61: 118-22.
4. Cohen S B, Dnes D M, Moorman C T. Familial calcification of the superior transverse scapula ligament causing neuropathy. Clin Orthop Rel Res. 1997; 334: 131-135.
5. Ticker J B, Djurasovic M, Strauch R J, April E W, Pollock R G, Flatow E L, Bigliani L U. The incidence of ganglion cysts and variations in anatomy along the course of the suprascapular nerve. J Shoulder Elbow Surg. 1998; 7 (5): 472-478.
6. Hrdlicka A. The scapula: Visual observations. Am J Phys Anthropol. 1942; 2: 73-94.

ORIGINAL ARTICLE

7. Khan M A. Complete ossification of the superior transverse scapular ligament in an Indian male adult. *Int J Morphol*. 2006; 24 (2): 195-6.
8. Thompson W, Kopell H. Peripheral entrapment neuropathies of the upper extremity. *N Engl J Med* 1959; 260: pp.1261-1265.
9. S D Jadhav, R J Patil, P P Roy, M P Ambali, M A Doshi, Rajeev R Desai. Supra scapular foramen in Indian dry scapulae. *National Journal of Clinical Anatomy*. 2012; 1 (3): 133-135.
10. Silva J G, Abidu-Figueiredo M, Fernandes R M P, Aureliano-Rafael F, Sgrott E A, Silva S F, Babinski M A. High Incidence of Complete Ossification of the Superior Transverse Scapular Ligament in Brazilians and its Clinical Implications. *Int J Morphol*. 2007; 25 (4): 855-859.
11. Osuagwu F C, Imosemi I O, Shokunbi M T. Complete ossification of the superior transverse scapular ligament in a Nigerian male adult. A case report. *Int J Morphol*. 2005; 23 (2): 121-122.
12. Srijit Das, Rajesh Suri, Vijay Kapur. Ossification of Superior Transverse Scapular Ligament and its Clinical Implications. *Sultan Qaboos University Medical Journal*. 2007; 7 (2): 157-160.
13. Edelson JG. Bony bridges and other variations of the suprascapular notch. *J Bone Joint Surg Br*. 1995; 77: 505-6.
14. Mahato RK, Suman P. Ossification of superior transverse scapular ligament: incidence, etiological factors and clinical relevance. *Int J Health Sci Res*. 2013; 3 (9): 14-21.
15. Polguy M, Jędrzejewski K S, Podgórski M, Topol M. Correlation between morphometry of the suprascapular notch and anthropometric measurements of the scapula. *Folia Morphol (Warsz)*. 2011; 70 (2): 109-15.
16. Mistry P, Chuhan K, Mehta C, Patil D, Bansal M, Suthar K. A study of incidence of ossification of superior transverse scapular ligament of scapula and its clinical implications. *Int J of Basic & Applied Medical Sciences*. 2013; 3 (2): 41-45.
17. Kalpana Thounaojam, Renuca Karam, N. Saratchandra Singh. Ossification of transverse scapular ligament. *Journal of Evolution of Medical & Dental Sciences*. 2013; 2 (12): 1790-91.
18. Natsis K, Totlis T, Tsikaras P, Appell HJ, Skandalakis P, Koebeke J. Proposal for classification of the suprascapular notch: a study on 423 dried scapulas. *Clin Anat*. 2007; 20: 135-9
19. Sinkeet SR, Awori KO, Odula PO, Ogeng'o JA, Mwachaka PM. The suprascapular notch: its morphology and distance from the glenoid cavity in a Kenyan population. *Folia Morphol (Warsz)*. 2010; 69: 241-245.
20. Sandow MJ, Ilic J. Suprascapular nerve rotator cuff compression syndrome in volleyball players. *Journal of Shoulder and Elbow Surgery*. 1998; 7 (5): 516-521.
21. Rengachary S S, Burr D, Lucas S, Hassanein K M, Mohn M P, Matzke H. Suprascapular entrapment neuropathy: A clinical, anatomical, and comparative study. Part 1-Clinical study. *Neurosurg*. 1979; 5: 441-46.
22. Rengachary S S, Burr D, Lucas S, Hassanein K M, Mohn M P, Matzke H. Suprascapular entrapment neuropathy: A clinical, anatomical, and comparative study. Part 2. Anatomical study. *Neurosurg*. 1979; 5: 447-51.
23. De Mulder K, Marynissen H, Van Laere C. Arthroscopic transglenoid suture of Bankart lesions. *Acta Orthop Belg*. 1998; 64: 160-66.
24. Warner JJP, Krushell RJ, Masquelet A, Gerber C. Anatomy and relationships of suprascapular nerve: anatomical constraints to mobilization of the supraspinatus and infraspinatus muscles in management of massive rotator-cuff tears. *J Bone Joint Surg Am*. 1992; 74: 36-45.

ORIGINAL ARTICLE

25. Bigliani LU, Dalsey RM, Mc Cann PD, April EW. An anatomical study of suprascapular nerve. *Arthroscopy*. 1990; 6: 301-05.
26. Polguy M, Jędrzejewski K, Majos A, Topol M. Variations of bifid superior transverse scapular ligament as a possible factor of suprascapular entrapment: A anatomical study. *International Orthopaedics* 2012; 36: 2095–2100.
27. Bayramoğlu A, Demiryürek D, Tüccar E, Erbil M, Aldur MM, Tetik O, Doral MN. Variations in anatomy at the suprascapular notch possibly causing suprascapular nerve entrapment: an anatomical study. *Knee Surg Sports Traumatol Arthrosc* 2003; 11: 393–398.
28. Wang HJ, Chen C, Wu LP, Pan CQ, Zhang WJ, Li YK. Variable morphology of suprascapular notch: an investigation and quantitative measurements in Chinese population. *Clin Anat*. 2011; 24: 47-55.
29. Black KP, Lombardo JA. Suprascapular nerve injuries with isolated paralysis of the infraspinatus. *Am J Sports Med*. 1990; 18: 225-228.
30. Kajava, Y. Über den Schultergiirtel der Finen. *Ann Acad Sci. Fenn, Series A*. 1924; 21 (5): 1-69.
31. Vallois HV. L'os acromial dans les races hummaine. *L'Anthropologie, Paris*. 1925; 35: 977-1022.
32. Muralidhar Reddy Sangam, Sattiraju Sri Sarada Devi, Karumanchi Krupadanam, Kolla Anasuya: A Study on the Morphology of the Suprascapular Notch and Its Distance from the Glenoid Cavity. *J Clin Diagn Res*. 2013; 7 (2): 189- 192.
33. Pragna Patel, S V Patel, S M Patel, Badal Jotania, Sanjay Chavda, Dhara Patel. Study of variation in the shape of the suprascapular notch in dried human scapula. *Int J Bio Med Res*. 2013; 4 (2): 3162-3164.
34. Vasudha TK, Ashwija Shetty, Sadashivana Gowd, Rajasekhar SSSN. Morphological study on suorascapular notch and superior transeverse scapular ligaments in human scapulae. *J Med Res Health Sci*. 2013; 2 (4): 793-798.
35. Udayasree L, Siva Prasad G V, Lakshmi V V V. Study of Anatomical Variations in the Shape of Suprascapular Notch in Dried Human Scapulae and its Clinical Significance. *Journal of Evolution of Medical and Dental Sciences* 2014; 3 (22): 6053-6057, DOI: 10.14260/jemds/2014/2704.

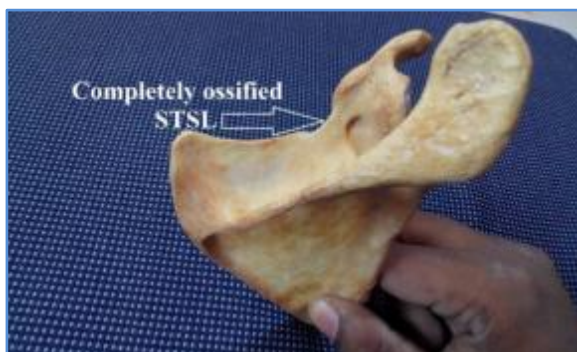

Fig. 4: Completely ossified STSL in right sided scapula

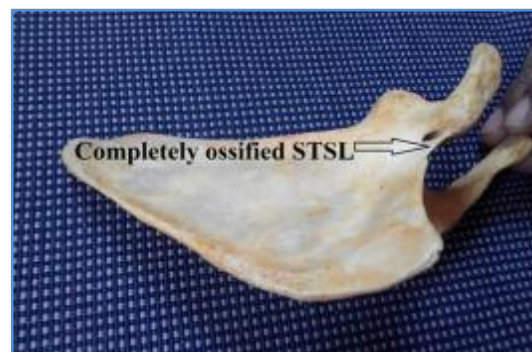

Fig. 5: Completely ossified STSL in right sided scapula (costal view)

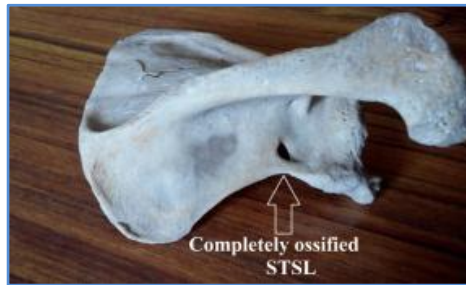

Fig. 6: Completely ossified STSL in left sided scapula

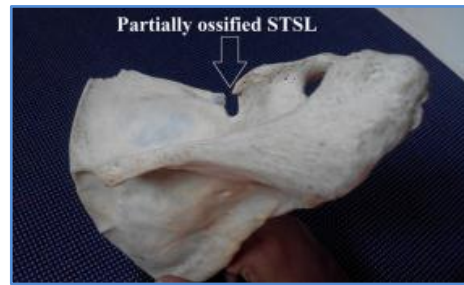

Fig. 7: Partially ossified STSL in right sided scapula

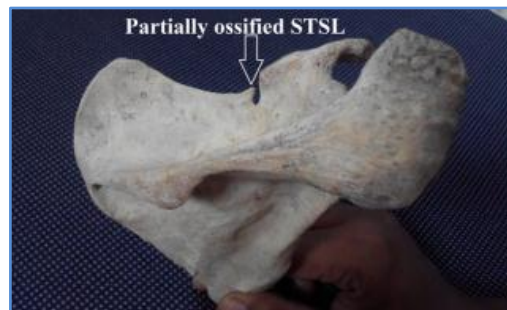

Fig. 8: Partially ossified STSL in right sided scapula

AUTHORS:

1. Md. Jawed Akhtar
2. Premjeet Kumar Madhukar
3. Nafees Fatima
4. Avanish Kumar
5. Binod Kumar
6. Rajiv Ranjan Sinha
7. Vinod Kumar

PARTICULARS OF CONTRIBUTORS:

1. Senior Resident, Department of Anatomy, Indira Gandhi Institute of Medical Sciences, Sheikhpura, Patna, Bihar.
2. Assistant Professor, Department of Anatomy, Lord Buddha Koshi Medical College & Hospital, Saharsa, Bihar.
3. Assistant Professor, Department of Anatomy, F. I. Maulana Ali Mian Institute of Medical Sciences, Unnao, U. P.
4. Associate Professor, Department of Anatomy, Indira Gandhi Institute of Medical Sciences, Sheikhpura, Patna, Bihar.

5. Assistant Professor, Department of Anatomy, Indira Gandhi Institute of Medical Sciences, Sheikhpura, Patna, Bihar.
6. Assistant Professor, Department of Anatomy, Indira Gandhi Institute of Medical Sciences, Sheikhpura, Patna, Bihar.
7. Professor & HOD, Department of Anatomy, Indira Gandhi Institute of Medical Sciences, Sheikhpura, Patna, Bihar.

NAME ADDRESS EMAIL ID OF THE CORRESPONDING AUTHOR:

Dr. Md. Jawed Akhtar,
Senior Resident,
Department of Anatomy,
Indira Gandhi Institute of Medical Sciences,
Sheikhpura, Patna-800014,
Bihar, India.
Email: drjawedakhtarpmch@gmail.com

Date of Submission: 10/11/2014.
Date of Peer Review: 11/11/2014.
Date of Acceptance: 17/11/2014.
Date of Publishing: 19/11/2014.