

CASE REPORT

GIANT BASAL CELL CARCINOMA IN THE POST AURAL REGION

T. D. Thimmappa¹, Ramesh S², Gangadhara K. S³, Hamsa Shetty⁴, Harshavardhan Kushal Shetty⁵

HOW TO CITE THIS ARTICLE:

T. D. Thimmappa, Ramesh S, Gangadhara K. S, Hamsa Shetty, Harshavardhan Kushal Shetty. "Giant basal cell Carcinoma in the Post Aural Region". Journal of Evolution of Medical and Dental Sciences 2013; Vol2, Issue 31, August 5; Page: 5768-5772.

ABSTRACT: Basal cell carcinoma (BCC) is a most common cutaneous malignancy now a day. The Giant BCC, defined as a lesion with more than 5 cm at its largest diameter Basal cell carcinoma occurs most commonly in the mid-face followed by the ear. When this lesion appears on the auricle, it is found primarily on the posterior surface of the auricle, followed by the pre-auricular & then the retro-auricular areas. Of the many sites mentioned in the literature, not many of the retro-auricular BCC have been reported in journals. Here we report a case of giant BCC in retroauricular region.

KEY WORDS: Giant Basal cell carcinoma, Retroauricular region, Excision biopsy

INTRODUCTION: Basal cell carcinoma (BCC) is a most common cutaneous malignancy also referred to as "Rodent ulcer" arises from the cells in the basal layer of the epidermis.

Sixty five to 85% of all BCC occur on the head & neck & 12 % of these are found on the auricle. The incidence of BCC is much lower in darker skinned ethnic groups than in Caucasians; patched gene is thought to be crucial in the pathogenesis of BCC & occurs most frequently in people over 45 years of age. The clinicopathological subtypes of BCC: ⁽⁶⁾

A) Gross

Localised: Nodular, nodulo-cystic, cystic, pigmented and naevoid.

Generalised: a.) Superficial (multifocal or superficial spreading)

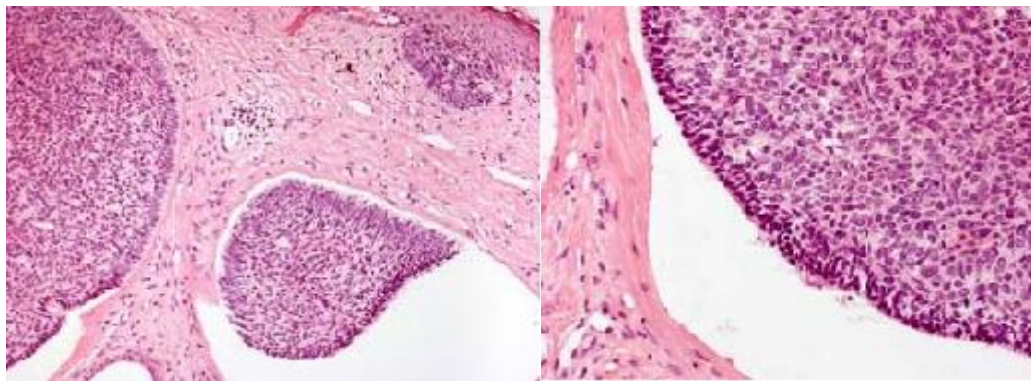
b.) Infiltrative (morphaic, ice-pick or cicatrizing)

NOTE ON HISTOLOGY: Characteristic finding is of ovoid cells in nests with a single, outer 'palisading' layer.

It is only the outer layer of cells that actively divide which explains why the tumor growth is slower than cell cycle speed would suggest, and why incompletely excised tumors are more aggressive.

The only exception to this is Morphaic BCC's which spread rapidly due to synthesis of type IV collagen.

CASE REPORT



BCC is a locally invasive, slow growing tumor that rarely metastasizes. It occurs exclusively on hairy skin, usually above a line from the lobe of the ear to the corner of the mouth. In this article, we describe a very rare presentation of BCC that was present in retroauricular region.

Investigations: (6) Wedge biopsy from the edge and visualization under microscope helps to confirm the diagnosis. Other routine blood and urine investigations are also done. Immunocompromised state affects the prognosis with higher rates of recurrence and delayed healing.

Management: (6) Treatment may be surgical or non-surgical. But wide-excision is the rule. When margins are ill-defined or tissue is at a premium (nose, eyes, ear), either Moh's micrographic surgery or a two-stage surgical approach with subsequent reconstruction after confirmation of clear margins is advisable. Moh's micrographic surgery aims at minimizing excision and maximizing conservation of tissues.

CASE REPORT: A 48 years old female presented to the otorhinolaryngology outpatient department of SIMS with ulcerative lesion behind the right ear of one year duration. She also had history of pain in the ulcer. She had no history of trauma, diabetes mellitus or burns.

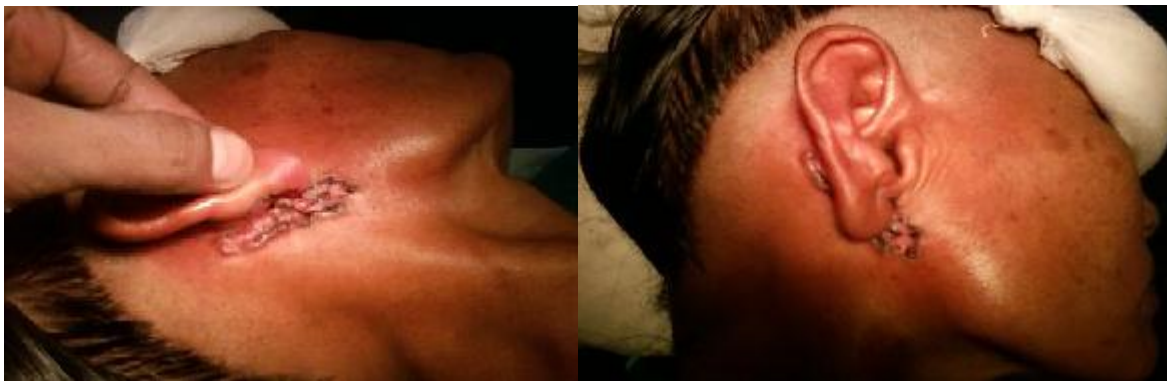On examination there was a 7×3cm size ulcerative lesion present at the right retroauricular region involving medial side of ear lobule with raised margin, indurated base & serosanguinous discharge. The systemic examination, vitals, laboratory investigation were within normal physiological limits.

The patient was sent to the dermatologist to seek their opinion.

We did wide-excision of the lesion including 2mm fresh skin & half of the ear lobule followed by primary closure. Patient was evaluated after 1 month no signs of recurrence.

On histopathological examination, the stained section showed uniform darkly stained basaloid cells with oval nuclei & relatively little cytoplasm. The cells were arranged into well demarcated islands & strands. Based on these facts it was reported as BCC.

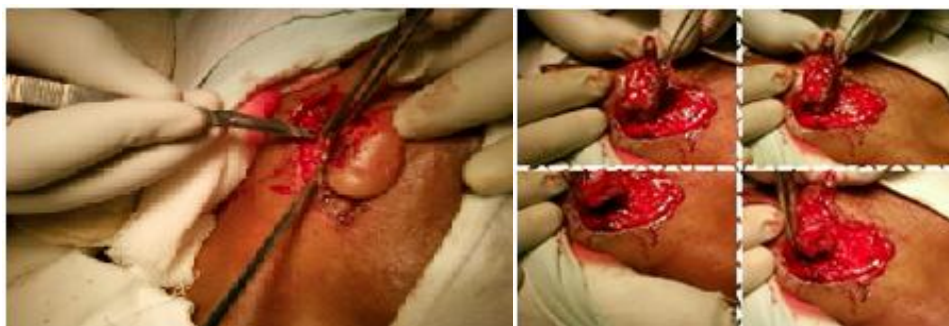CASE REPORT



Pre-operative (BCC in right retroauricular region)

DISCUSSION: BCC is a type of skin cancer, 65-85% found in head & neck region. In head & neck region 12% of lesion are found on the auricle. It is found primarily on the posterior surface of auricle followed by the preauricular & then the retroauricular areas^{1,2}. Sun exposure is the number one risk factor for the development of BCC. Genetic factor is also an important factor, in that loss of heterozygosity for chromosome 9q markers³. There are several pathological types of BCC that differ in their appearance histologically & grossly & in their behavior. They are nodular, ulcerative, pigmented, superficial, morphea form/sclerosing & basaloid squamous⁴.

Nodular BCC is the most common variant & least aggressive. When this nodular outgrows its blood supply & the central portion necrosis occurs, it forms ulcerative BCC i.e. classic rodent ulcer². Patient often report a slowly enlarging lesion that does not heal & that bleeds when traumatized⁵. BCC grow slowly, taking months or even years to become sizeable. Although spread to other parts of the body is very rare, a BCC can damage & disfigure the ear, eye & nose if it grows nearby⁶.



Intra-operative

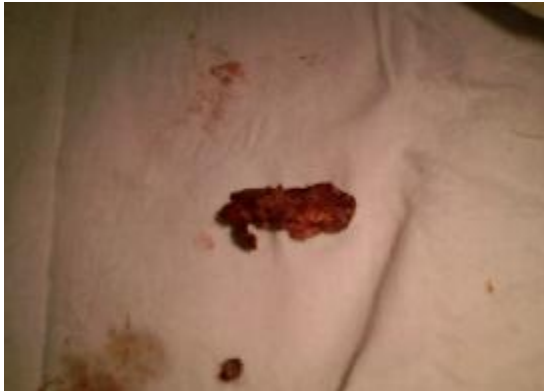Diagnosis is made through natural history, physical examination & biopsy. Lesions that have changed in color, size or shape or that are friable or ulcerated should be biopsied⁷. Histologically BCC are made up of nests of basaloid cells with peripherally palisading cells. The cells have hyperchromatic nuclei & scant cytoplasm. Mitotic figures are common⁸.

The treatment options for BCC are curettage & cautery, excision biopsy, Moh's micrographically controlled excision, photodynamic therapy, Imiquimod cream application,

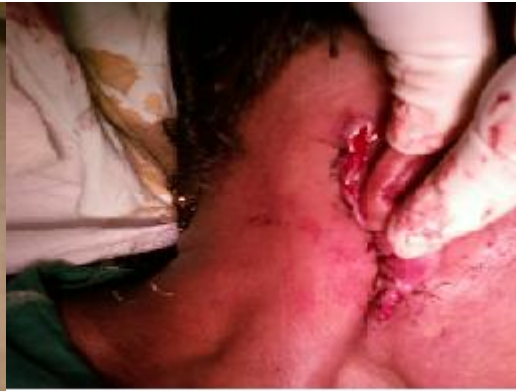CASE REPORT

cryotherapy or radiotherapy are the other options depending on its type, size & location, the number to be treated & the preference or expertise of the doctor⁹.

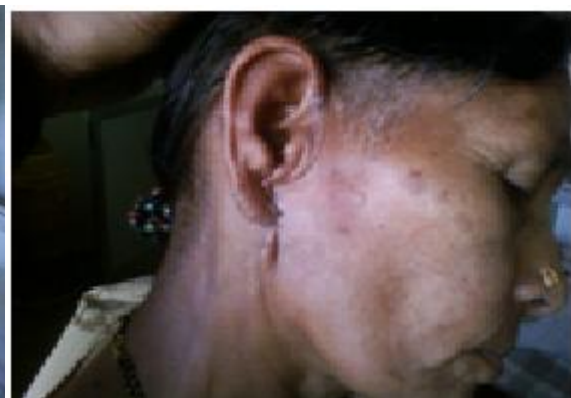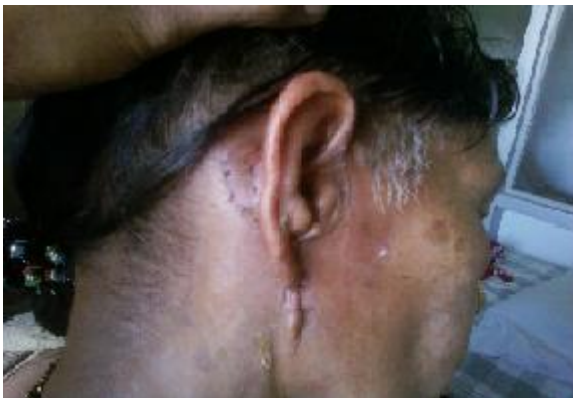In our case report, the lesion was present in right retroauricular region which is very rare. It presented as a very slow growing non-healing ulcer. After the patient gave informed consent to undergo surgery, we performed excision biopsy of the lesion & primary closure, saving half of the ear lobule.



Excised Portion



Primary closure of wound



After one month in post-operative period

CONCLUSION: We report a very rare presentation of BCC in retroauricular region. Otorhinolaryngologist must keep a differential diagnosis of BCC in case of ulcerative lesion present in retroauricular region apart from lupus vulgaris, lupus erythematosus, melanoma, and squamous cell carcinoma. Tumors >2cm size and occurring in uncommon sites are known to recur. Hence complete & meticulous excision with primary closure gives best results. In most cases the treatment of choice is surgery, whose main purpose is to eradicate the lesion and to maintain good cosmetic appearance.

REFERENCES:

1. Glasscock-Shambaugh, surgery of the ear (2003): 369-371.
2. Stell and Maran's Head & Neck Surgery, Fourth edition; 409-410.

CASE REPORT

3. Clinicopathologic analysis of 60 cases of BCC. Zhang B, Wang N, Hew Chin. Med Sci.J.1993jun 8(2); 121-122.
4. Medscape; oncology – carcinoma of the skin. Robert S Bader. MD. Dermatologist North Broward Medical centre Aug 31, 2009.
5. Journal of the American Academy of family Physicians. Oct. 15, 2004. Vol.70/no.8. Diagnosis & treatment of BCC & SCC
6. Bailey and Love's Short Practice of Surgery 25th edition pg. 611 Skin tumors
7. Basal cell carcinomas of the auricular region: a study of 23 cases.

AUTHORS:

1. T. D. Thimmappa
2. Ramesh S.
3. Gangadhara K. S.
4. Hamsa Shetty
5. Harshavardhan Kushal Shetty

PARTICULARS OF CONTRIBUTORS:

1. Associate Professor and HOD, ENT, Department of Otorhinolaryngology, Shimoga Institute of Medical Sciences.
2. Assistant Professor, ENT, Department of Otorhinolaryngology, Shimoga Institute of Medical Sciences.
3. Professor, ENT and Director SIMS, Department of Otorhinolaryngology, Shimoga Institute of Medical Sciences.

4. Junior Resident, Department of Otorhinolaryngology, Shimoga Institute of Medical Sciences.
5. House Surgeon, Department of Otorhinolaryngology, Shimoga Institute of Medical Sciences.

NAME ADDRESS EMAIL ID OF THE CORRESPONDING AUTHOR:

Dr. T.D. Thimmappa,
Associate Professor and HOD, ENT,
Government McGann Teaching Hospital,
SIMS, Shimoga.
Email – drtdthimmappa@yahoo.com

Date of Submission: 03/07/2013.
Date of Peer Review: 06/07/2013.
Date of Acceptance: 20/07/2013.
Date of Publishing: 31/07/2013