

**POSITION OF CEREBELLAR TONSILS IN REFERENCE TO FORAMEN MAGNUM: AN MRI STUDY**A. S. Lakshmi<sup>1</sup><sup>1</sup>*Additional Professor, Department of Anatomy, Medical College, Trichur, Kerala.*

**ABSTRACT:** Normal position of the cerebellar tonsils is described to be at or above the foramen magnum. Western studies have shown the cerebellar tonsils to be below the foramen magnum. Position of tonsils is of great importance in assessing the hind brain deformity–Chiari malformation. There are no Indian studies to corroborate the findings. Hence, we proposed a basic study to find out the existence of tonsillar ectopia (Position of tonsils below the foramen magnum) in normal population. Our study was conducted for a period of 8 months at the Radiology Department of SCTIMST, Trivandrum, Kerala; 515 patients with normal brain, spinal cord and normal craniovertebral junction (CVJ) were selected from a group of patients who underwent MRI investigation of brain and cervical spine for various vague complaints. They ranged from 2 months to 80 years and of both sexes. Patients with raised intracranial tension and established CVJ anomalies were excluded. The study was done on the MR images obtained on the MR monitor directly during the scan. Foramen magnum and the inferior extent of cerebellar tonsils were marked. The position of the tonsils was noted in reference to foramen magnum and the data analysed. Tonsillar ectopia was noticed in 21% of the population. A downward descent in the position was observed in the fifth decade of life. In infancy and old age, higher positions were noted. The study indicates that the position of the tonsils below the foramen magnum is a normal occurrence.

**KEYWORDS:** Foramen Magnum, Brain, Cerebellar Tonsils, Chiari Malformation.

**HOW TO CITE THIS ARTICLE:** A. S. Lakshmi. "Position of Cerebellar Tonsils in Reference to Foramen Magnum: An MRI Study." *Journal of Evolution of Medical and Dental Sciences* 2015; Vol. 4, Issue 94, November 23; Page: 15970-15974, DOI: 10.14260/jemds/2015/2327.

**INTRODUCTION:** According to standard textbooks of anatomy,<sup>1</sup> cerebellar tonsils are situated above the foramen magnum, although occasionally it may pass through the foramen magnum. However, Western studies<sup>2,3,4</sup> have shown various degrees of cerebellar ectopia as normal occurrence. No Indian studies are available for corroboration. Cerebellar tonsils attain a position below the foramen magnum in pathological conditions with raised intracranial tension. This may be due to space occupying lesions of the brain (e.g. tumours, bleeding etc.) and congenital hind brain herniation.

Arnold-Chiari malformation is a congenital disorder manifesting in late adulthood. It runs in families and manifests with diverse symptoms like motor deficits (e.g. monoparesis, hemiparesis, paraparesis), hypalgesia, analgesia, bladder dysfunction, dysphasia, dysphagia, respiratory abnormalities, syncope, vertigo, visual disturbances etc. The patients usually come to the hospital at a later stage of the disease where management is very difficult and with a bad outcome. Patients suffer with neuronal deficits for the rest of their lives.

Hospital records show a frequent occurrence of Chiari malformation in Kerala. Position of the cerebellar tonsils is of great importance in assessment of Chiari malformation. Since this is a medical enigma, a preliminary study was

proposed to determine the position in normal population.

This could help differentiate the normal and the pathological conditions.

**MATERIALS AND METHODS :** This study was conducted on 515 patients during MRI investigation at the Radiology Department of the Sree Chithra Tirunal Institute of Medical Science and Technology (SCTIMST) in Trivandrum, Kerala, over a period of 8 months. The subjects were chosen from a group of patients who underwent MRI scan for various vague complaints like headache, body ache, weakness etc. After MRI, patients with normal brain and spinal cord with normal cranio-vertebral junction (CVJ) were selected.

The patients ranged from 2 months of age to 80 years in both sexes. Patients with raised intracranial tension and established CVJ anomalies were excluded. The equipment consisted of a super conducting magnet of 1.5 Tesla, manufactured by General Electric, USA.

Personal data of the patients was recorded. Height and weight of the patients were noted. During the MRI scan the brain, spinal cord, ventricles and CVJ region were thoroughly examined to rule out pathology. The cerebellar tonsils were specially noted for their position with reference to foramen magnum and symmetry.

The foramen magnum was identified by joining the line from Basion (Marked 'A') to Ophisthion (Marked 'B'). The bones were easily identified by their low signal intensity. The inferior extent of cerebellar tonsils was marked 'C' and its position noted in reference to 'AB' (Figure 1). The data was analysed using the computer package SPSS/PC. The statistical tests included student t-test and chi-square test.

*Financial or Other, Competing Interest: None.*

*Submission 01-11-2015, Peer Review 02-11-2015,*

*Acceptance 13-11-2015, Published 23-11-2015.*

*Corresponding Author:*

*Dr. A. S. Lakshmi,*

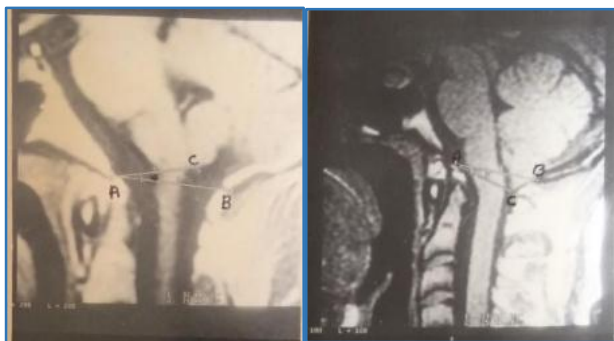
*Additional Professor,*

*Department of Anatomy,*

*Medical College, Trichur-680596, Kerala.*

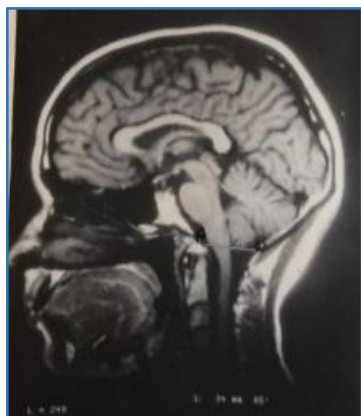*E-mail: lakshmipadmanabhanblr@gmail.com*

*DOI:10.14260/jemds/2015/2327.*



Above Foramen Magnum

Below Foramen Magnum



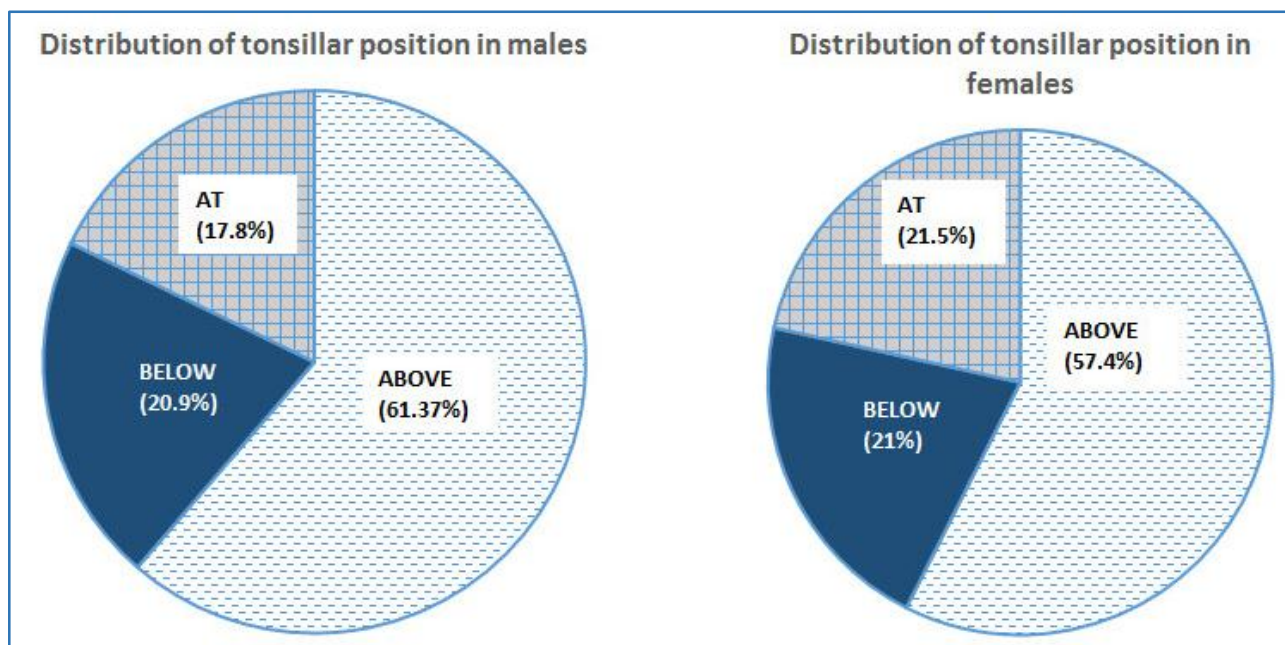
At Foramen Magnum

**Fig. 1: Cerebellar Tonsils Position with Respect to Foramen Magnum.**

**RESULTS:** The study showed 21% of the sample had cerebellar tonsils below the foramen magnum and 79% at or above the foramen magnum (Figure 2). In both males and females, the incidence of cerebellar tonsillar ectopia was the same [20.9% in males and 21% in females]. Maximum number of cerebellar tonsillar ectopia was noticed in the fifth decade of life. This was followed by an ascent in the position in the seventh decade in both sexes (Table 1 and Figure 3, Table 2 and Figure 4). In infancy and old age, the position of tonsils was found to be above the foramen magnum (Table 1 and Figure 3, Table 2 and Figure 4).

In 98.6% of the population, right and left tonsils were symmetric in position. Asymmetry was noticed in 1.4% of the population. Asymmetry was noticed to be 0.2% higher in females (1.3% in males and 1.5% in females). In 80% of the subjects with asymmetric position of tonsils, ectopia was observed.

No relationship was found between the BMI (Body Mass Index) and the position of cerebellar tonsils.



**Fig. 2: Distribution of Tonsillar Position with reference to Foramen Magnum in Males and Females**

Age	Above Foramen Magnum	Below Foramen Magnum	At Foramen Magnum
< 1 year	5 (100.0%)	0	0
1 - 4 years	7 (63.63%)	3 (27.27%)	1 (9.09%)
5 - 9 years	7 (43.75%)	4 (25%)	5 (31.25%)
10 - 14 years	6 (40.00%)	2 (13.33%)	7 (46.66%)
15 - 19 years	13 (76.47%)	2 (11.76%)	2 (11.76%)
20 - 29 years	43 (68.25%)	9 (14.28%)	11 (17.46%)
30 - 39 years	34 (57.62%)	16 (27.11%)	9 (15.25%)
40 - 49 years	30 (55.55%)	18 (33.33%)	6 (11.11%)
50 - 59 years	34 (64.15%)	8 (15.09%)	11 (20.74%)
60 - 69 years	10 (55.55%)	4 (22.22%)	4 (22.22%)
70 and above	7 (77.77%)	1 (11.11%)	1 (11.11%)

**Table 1: Distribution of Tonsillar Position with respect to Foramen Magnum in Different Age Groups Among Males**

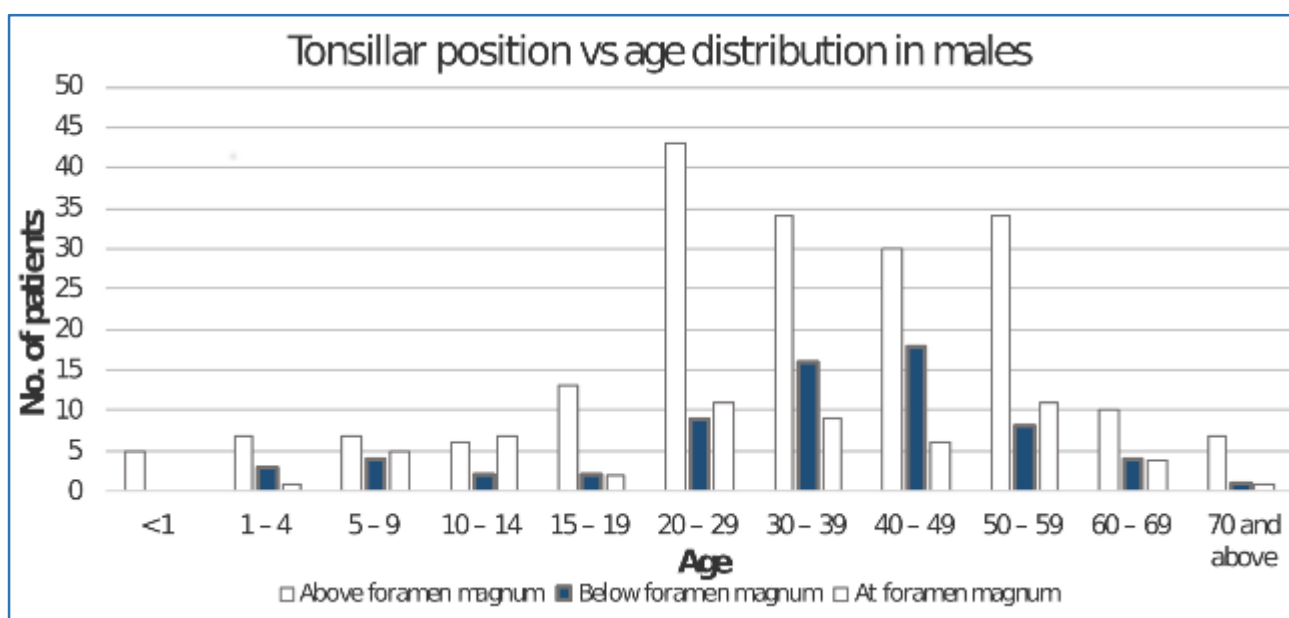
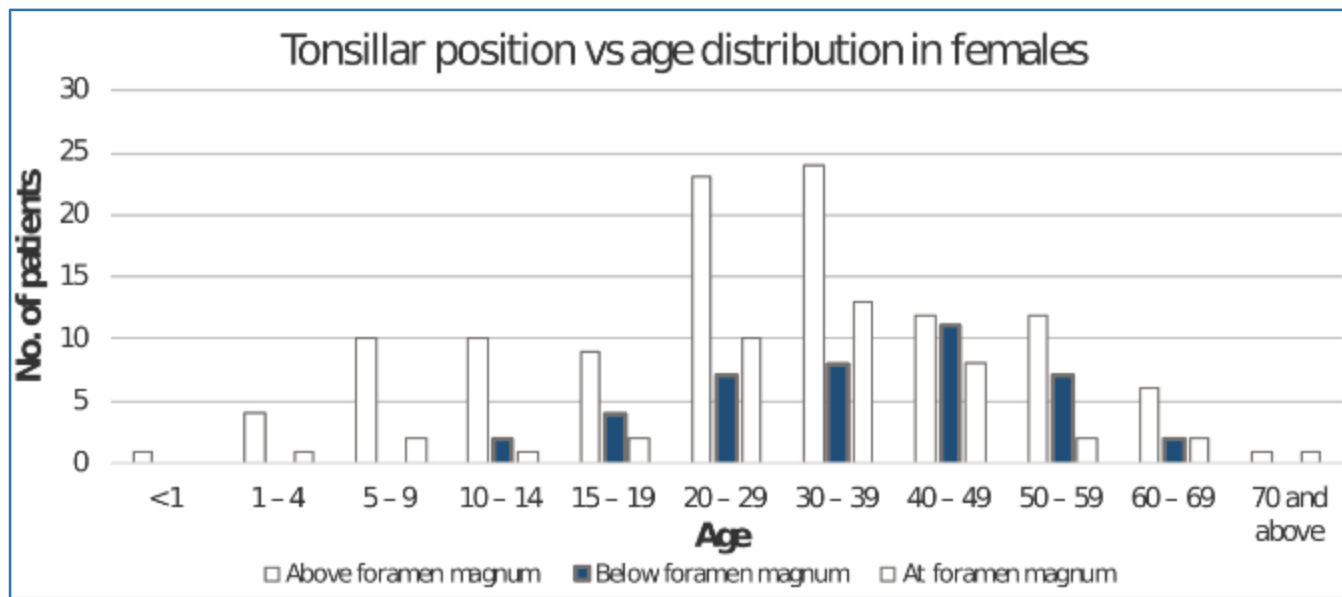


Fig. 3: Tonsillar Position for Different Age Groups in Males

Age	Above foramen magnum	Below foramen magnum	At foramen magnum
< 1 year	2 (100.0%)	0	0
1 - 4 years	4 (80.00%)	0	1 (20.00%)
5 - 9 years	10 (83.33%)	0	2 (16.66%)
10 - 14 years	10 (76.92%)	2 (15.38%)	1 (7.69%)
15 - 19 years	9 (60.00%)	4 (26.66%)	2 (13.33%)
20 - 29 years	23 (57.50%)	7 (17.50%)	10 (25.00%)
30 - 39 years	24 (53.33%)	8 (17.77%)	13 (28.88%)
40 - 49 years	12 (38.71%)	11 (35.48%)	8 (25.81%)
50 - 59 years	12 (57.14%)	7 (33.33%)	2 (9.52%)
60 - 69 years	6 (60.00%)	2 (20.00%)	2 (20.00%)
70 and above	1 (50.00%)	0	1 (50.00%)

**Table 2: Distribution of Tonsillar Position with respect to Foramen Magnum in Different Age Groups Among Females**



**Fig. 4: Tonsillar Position for Different Age Groups in Females**

**DISCUSSION:** In our study, among 515 patients, 79% had the cerebellar tonsils above or at the foramen magnum. Tonsillar ectopia was observed in 21% of the normal population.

When the position was compared between males and females, no significant difference was noticed in the frequency of tonsillar ectopia (Figure 2, Figure 3 and Figure 4). Males showed a frequency of 20.9% and females showed 21%. The 0.1% difference between males and females can be considered negligible. Allen D. Elster.<sup>5</sup> had observed a female predominance of Chiari malformation with a female-to-male ratio of 3:2 by MR imaging.

In our study, all the subjects during infancy and majority of those above 70 years had cerebellar tonsils above the foramen magnum. Tonsillar ectopia was more commonly noticed in the age group of 40-49 years (Figure 3 and Figure 4).

An MRI study by David Mikulis.<sup>3</sup> showed the position of tonsils to be below foramen magnum in young individuals and the position went up as age advanced. In our study, higher tonsillar position in the 70 and above age group was comparable to a similar finding in the older age group by David Mikulis. Further, David Mikulis, in his study has shown a linear ascent in the position with age. However, linear ascent is not seen in our study.

A remarkable observation in the present study was the downward descent in the position of the tonsils around the fifth decade of life, which was followed by a gradual ascent in the seventh decade of life. The hypothetical interpretation of the descent may be due to degenerating changes commencing around the fifth decade in cerebellar tonsils. Deposition of certain degenerating substances may cause relative increase in the size of cerebellar tonsils, which may give rise to the descent in the position of the tonsils. Later on gradual atrophic changes in the brain may cause shrinkage of tissues resulting in relatively higher positions of cerebellar tonsils in the seventh decade.

In 98.6% of the population right and left tonsils were symmetric in position; 1.4% showed asymmetry with females having a higher incidence of 0.2%. Bloch.<sup>4</sup> reported asymmetry between right and left tonsils by myelography. Allen D. Elster.<sup>5</sup> reported asymmetry in 6 ACM patients. Further, Elster stated that the patients did not have specific symptoms due to this feature. Further, he observed the female predominance in ACM.

No correlation could be established between the BMI and the position of the tonsils. Hence, it was concluded that the build of the individual did not influence the position of the cerebellar tonsils. There were no studies available to compare this finding. However, Ishikawa.<sup>6</sup> reported the tonsillar position to be at or above the foramen magnum in his study among Japanese population. David Mikulis.<sup>3</sup> had commented that this could be due to the existence of genetic differences among different races, which could influence the tonsillar position. Race may influence the build, but build need not influence the tonsillar position as evident from the present study.

**CONCLUSION:** The study has given a valuable insight that 21% of the normal population may have tonsillar ectopia. This gives scope for further studies to analyze the degree of ectopia and relate that in pathological conditions.

#### REFERENCES:

1. Williams et al., Gray's Anatomy 1995, 38th edition, Churchill Livingstone.
2. Aboulez A. O. et al., "Position of Cerebellar tonsils in the Normal population and in patients with Chiari malformation. A Quantitative Approach with MR Imaging," J. Comp. Asst. tomography 1985, 9, pp 1033-1036.
3. David Mikulis et al., "Variance of the position of cerebellar tonsils with age: Preliminary report," Radiology 1992, 183, pp 725-728.

4. Bloch S., Van Reneberg, M. J. Danziger, "The Arnold-Chiari Malformation," *Clinical Radiology* 1974, 25, pp 335-341 (cited in *AJNR* 1986, 7, pp 795-799).
5. Allen D. Elster et al., "Chiari I Malformations, Clinical and Radiologic reappraisal," *Radiology* 1992, 183, pp 347-353.
6. Ishikawa M. et al., "Tonsillar herniation on MRI," *Neurosurgery* 1988, 22, pp 77-80.